

From: Dr. Deborah Davis [REDACTED]

Sent: Wednesday, 6 May 2015 11:29 AM

To: medboardconsultation

Subject: FW: Consultation Cosmetic medical and surgical procedures provided by medical practitioners¹

To the Medical Board of Australia

Re: Feedback on draft cosmetic surgery guidelines - Medical mandatory face-to-face consultations before prescribing schedule 4 (prescription only) cosmetic injectables

My sole field of medical practice since 1988 has been non-surgical cosmetic medicine. During numerous years since then, according to the suppliers of Botox and Restylane fillers, my practice has been the largest user of Botox and second largest user of Restylane products in Australasia.

I strongly support the requirement for a face to face consultation for consideration of treatment with prescription muscle relaxants and dermal fillers. A physical examination is required for the appropriate prescription of these products.

I have attached two articles describing consensus guidelines of expert panels for the use of the most common muscle relaxants and dermal fillers. Relevant excerpts from these articles are:

As faculty members pointed out, treatment planning and goals must take each individual's presentation into account to provide a harmonious, balanced outcome. Ethnic background and skin type add another dimension to the evaluation: sensitivity and consideration of cultural and ethnic aesthetic ideals and goals, such as maintaining ethnic identification while improving appearance. This is, however, in keeping with an essential guiding principle of aesthetic treatment: tailoring treatment realistically to specific individual goals and needs, which plays an important role in determining timing and use of specific products and ensuring high patient satisfaction.

Patient Selection Rather Than Product Selection May Be the Most Important Factor in Predicting Outcomes. The faces of some patients have a profound and obvious loss in one structural tissue only (a "one-tissue issue"), whereas others may show only slight loss in all structural layers.

We now know that the face does not age as one homogeneous object, but as many dynamic components that are best evaluated, modified, and augmented individually.

The variety of options affords clinicians and patients greater versatility in tailoring therapy to individual needs and goals.

The panel addressed ... tailoring of treatments to individual needs and circumstances, including ethnic and cultural considerations, such as skin type, facial shape.

One of the most important changes in facial rejuvenation has been a shift from a two-dimensional focus on hyperdynamic facial lines and immobilization of corresponding muscles to an increased comprehension and appreciation of the three-dimensional aspects of facial aging.

The faculty stressed, however, the importance of evaluating the overall patient presentation and assessing the effect of change in one area on others.

Due to the numerous factors contributing to the visible signs of aging, facial rejuvenation is likely to be best served by a multipronged approach

A comprehensive consultation and physical examination with the prescribing practitioner is required to fulfil the recommendations of the experts panels in the attached articles. This is obviously not possible in a Skype consultation with a prescribing practitioner who is not in the same room and whose physical examination is by limited visual examination only.

Regards,

Dr Deborah Davis

MBBS(Hons) (Syd), BSc, BA

Fellow Australian College Aesthetic Medicine

Member Cosmetic Physicians Society of Australia.

Fellow and current Board Member Cosmetic Physicians College of Australia

Heber Davis

37 Bay St

Broadway NSW Australia 2007

Phone (+612) 9552 6277

Web: www.heberdavis.com.au

Advances in Facial Rejuvenation: Botulinum Toxin Type A, Hyaluronic Acid Dermal Fillers, and Combination Therapies—Consensus Recommendations

Jean D. A. Carruthers, M.D.
Richard G. Glogau, M.D.
Andrew Blitzer, M.D., D.D.S.,
and the Facial Aesthetics
Consensus Group Faculty

Vancouver, Canada; San Francisco,
Calif.; and New York, N.Y.

Background: Facial aesthetics and rejuvenation are evolving rapidly due to changes in products, procedures, and patient demographics. Clinicians can benefit from ongoing guidance on products, tailoring treatments to individual patients, treating multiple facial areas, and using combinations of products and ways to optimize outcomes.

Methods: A multidisciplinary group of aesthetic treatment experts convened to review the properties and uses of botulinum toxin type A (BoNTA) and hyaluronic acid fillers and to update consensus recommendations for facial rejuvenation using these two types of products. The group considered paradigm shifts in facial aesthetics; optimal techniques for using BoNTA and hyaluronic acid fillers alone and in combination; the influence of patient sex, ethnicity, cultural ideals, and skin color on treatment; general techniques; patient education and counseling; and emerging trends and needs in facial rejuvenation.

Results: The group provided specific recommendations by facial area, focusing on relaxing musculature, restoring volume, and recontouring using BoNTA and hyaluronic acid fillers alone and in combination. For the upper face, BoNTA remains the cornerstone of treatment, with hyaluronic acid fillers used to augment results. These fillers are central to the midface because of the need to restore volume. BoNTA and hyaluronic acid in combination can improve outcomes in the lower face.

Conclusions: Optimal outcomes in facial aesthetics require in-depth knowledge of facial aging and anatomy, an appreciation that rejuvenation is a three-dimensional process involving muscle control, volume restoration, and recontouring, and thorough knowledge of properties and techniques specific to each product in the armamentarium. (*Plast. Reconstr. Surg.* 121 (Suppl.): 5S, 2008.)

Substantial and rapid change typifies the field of facial aesthetics and rejuvenation as physicians and patients continue their quest for minimally invasive yet highly effective and safe approaches to mitigate the signs of facial aging.^{1,2} In 2004, the publication *Consensus Recommendations on the Use of Botulinum Toxin Type A in Facial*

Aesthetics provided guidance on the use of the Botox formulation (Botox Cosmetic; Allergan, Inc., Irvine, Calif.) of botulinum toxin type A (BoNTA).³ Statistics for 2006, the latest available, show that BoNTA injection continues to be the single most common aesthetic procedure performed in men and women in the United States, but that its use is accompanied by growth in the use of other modalities, including dermal fillers.⁴

From the Department of Ophthalmology, University of British Columbia; Department of Dermatology, University of California, San Francisco; and Department of Otolaryngology—Head and Neck Surgery, Columbia University.

Received for publication November 5, 2007; accepted February 4, 2008.

The faculty of the Facial Aesthetics Consensus Group is listed in an Appendix at the end of this article.

Copyright ©2008 by the American Society of Plastic Surgeons

DOI: 10.1097/PRS.0b013e31816de8d0

Disclosures: *The faculty's financial relationships or relationships to products or devices they or their spouse/life partner have with commercial interests related to the content of this continuing medical education activity are listed in an Appendix at the end of this article.*

Nearly 3.2 million procedures were performed with BoNTA, and another 1.6 million procedures were performed with hyaluronic acid fillers, constituting about 81 percent of all procedures involving soft-tissue augmentation.⁴ Together, BoNTA and soft-tissue fillers comprise approximately 54 percent of all nonsurgical aesthetic procedures. With the fillers now available, such as the newer hyaluronic acid products, it can be anticipated that both demand and use will increase because the variety of options affords clinicians and patients greater versatility in tailoring therapy to individual needs and goals.

Changes have occurred not only in products but also in patient demographics, treatment goals, and the ways in which products are used. For example, in the year 2000, ethnic minorities accounted for approximately 15 percent of all minimally invasive procedures in the United States. In 2006, this had increased to approximately 22 percent. Men had 8 percent of all cosmetic procedures in 2006. Growth rates for BoNTA injection and use of hyaluronic acid fillers are higher in men than in women.^{4,5} Cultural and ethnic differences in aesthetic ideals and treatment goals are likely to have an increasing effect on how aesthetic medicine is practiced.

AN EVOLVING PARADIGM

One of the most important changes in facial rejuvenation has been a shift from a two-dimensional focus on hyperdynamic facial lines and immobilization of corresponding muscles to an increased comprehension and appreciation of the three-dimensional aspects of facial aging, particularly the loss of volume and its effect on treatment approaches.⁶ This change manifested itself initially in the idea of using BoNTA for facial shaping, but it has expanded to meld concepts of movement control, recontouring, and volume restoration using multiple modalities.^{2,7,8}

With changing aesthetics have come modifications in the way BoNTA is used in clinical practice. Although most clinical trials report results of BoNTA treatment on single areas of the face, clinicians tend to treat multiple areas to provide a more natural, relaxed look.^{9,10} Increasingly, too, BoNTA is used in combination with other modalities, including hyaluronic acid dermal fillers.¹¹ By using fillers in combination with BoNTA, it becomes possible to address facial rejuvenation from a three-dimensional rather than a two-dimensional approach, thereby providing more pleasing, longer-lasting aesthetic outcomes.

CLINICAL IMPLICATIONS

The rapid changes occurring in aesthetic medicine necessitated updated clinical recommendations to guide the practice of more advanced techniques. Specifically, areas to be addressed included the following:

- Understanding the importance of how differences among products of the same class influence clinical use and outcomes
- Treating multiple areas in a single session
- Tailoring treatments to individual needs and circumstances, including ethnic and cultural considerations, such as skin type, facial shape, and aesthetic ideals
- Using combinations of products
- Ensuring patient satisfaction

On April 13 to 15, 2007, a multidisciplinary group of experts in aesthetic treatments convened to review the properties and clinical implications of various BoNTA and hyaluronic acid filler formulations and to develop updated consensus recommendations for facial rejuvenation with more advanced techniques using these two types of products. Specifically, these experts addressed the following topics:

- Optimal techniques for using BoNTA and hyaluronic acid fillers alone and in combination to treat multiple upper, middle, and lower facial rhytides, volume depletion, and folds
- Effect of sex, ethnicity, cultural ideals, and skin color on treatment
- General techniques and patient education/counseling
- Emerging trends and needs in facial rejuvenation

For purposes of discussion, the face was divided into thirds (upper, middle, and lower). The faculty stressed, however, the importance of evaluating the overall patient presentation and assessing the effect of change in one area on others. They concurred that the goals of aesthetic treatments are to help patients feel more attractive and as satisfied with their appearance as possible, by creating and maintaining a harmonious, balanced, and refreshed look. This continuing medical education supplement represents a compilation of their recommendations, continuing the process begun in 2004. The specific recommendations made in this document reflect the consensus of this group based on their clinical experience as well as published data regarding the use of BoNTA and hyaluronic acid fillers. It should be noted that other treatments, including non-

hyaluronic acid fillers, may be suitable for facial rejuvenation in individual patients. Recommendations for optimizing their use may become available in the future.

BOTULINUM NEUROTOXINS AND HYALURONIC ACID FILLERS IN FACIAL AESTHETICS

Botulinum Neurotoxin Formulations

Botulinum neurotoxins are produced by various strains of *Clostridium botulinum*, resulting in seven known serotypes, of which A and B have been developed for routine clinical use.^{12,13} Although basic mechanisms of action are the same for the various types of toxins, they differ both between and within types in a number of properties that have important implications for clinical use.¹³ Of the major toxins available for clinical use, only two formulations of BoNTA have been studied and used extensively for both cosmetic and therapeutic indications (Table 1).^{14–16} The type B formulation, commercially available as Myobloc (Solstice Neurosciences, Inc, Malvern, Pa.), is indicated in the United States for the treatment of cervical dystonia. It was deemed less suitable and practical for cosmetic use by the consensus faculty members because of discomfort on injection due to its acidity (pH approximately 5.6) and its shorter duration of effect, which has also been reported in the literature.^{17,18} Therefore, the remainder of this discussion focuses on the two major formulations of BoNTA. Only one (Botox) is approved for a cosmetic use (to treat glabellar lines) by the U.S. Food and Drug Administration; the other (Dysport, Reloxin; Ipsen Limited, Berkshire, United Kingdom) is undergoing Food and

Drug Administration review and is indicated for aesthetic use in other countries.¹⁹

According to clinical studies, product labeling, and clinical experience, these two formulations are not interchangeable and cannot be substituted one for the other by any simple or fixed-dose conversion ratio. Perhaps one of the most important clinical considerations is the probability of diffusion or migration outside the targeted muscle. From both preclinical and clinical studies, it appears that the Dysport/Reloxin formulation is more likely to diffuse farther from the injection site.^{16,19,20} In addition, the duration of effect may differ, with the Botox formulation providing a longer response at a dose ratio of 2.5:1 (Dysport:Botox).²¹

The consensus faculty reported on their experience with the two formulations of BoNTA. All have used the Botox formulation, and 87 percent reported experience with Dysport/Reloxin in clinical studies. Approximately 50 percent also have used botulinum toxin type B (Myobloc). On the basis of their experience, most faculty members who have used both Botox and Dysport/Reloxin reported that injection volumes and doses differ, that injection patterns may need to be altered due to differences in migration, and that inexperienced injectors will likely have a steep learning curve to adjust injection techniques, because outcomes can differ substantially as a result of relatively minor differences in injection sites. They recommended that Dysport/Reloxin be used with caution around the eyes, upper lip, and depressor anguli oris and in the mentalis.

Hyaluronic Acids

Naturally occurring hyaluronic acids are present universally in living organisms as part of the extracellular matrix.^{22,23} For many years, forms of hyaluronic acids have been used for intra-articular joint injections and in ophthalmologic procedures such as cataract surgery.^{24,25} More recently, they have become important as dermal fillers and contouring agents.

Native hyaluronic acid has a short half-life of only about 1 to 2 days in tissue.²³ The process of cross-linking hyaluronic acid results in larger, more stable molecules that have biocompatibility and viscoelastic properties similar to those of the naturally occurring substance. Cross-linking causes the ordinarily hygroscopic gel to become less water-soluble, thereby increasing product stability in tissue. Properties of hyaluronic acids that are important in determining their clinical per-

Table 1. Comparisons between Formulations of Botulinum Toxin Type A

	Botox (Vistabel), Allergan, Inc.	Reloxin (Dysport), Ipsen Limited
FDA approval	Yes, cosmetic/ therapeutic	Pending, cosmetic/ therapeutic
Serotype	A	A
Complex molecular weight	900 kDa	500–900 kDa
Units per vial	100	500
Protein	~5 ng/vial	~5 ng/vial
Form	Vacuum-dried	Lyophilized
pH	~7.0	~7.0
Diffusion	Lower	Higher
Diluent (saline)	2.5 ml	5.0 to 7.5 ml

FDA, U.S. Food and Drug Administration.

formance include the concentration of hyaluronic acid and the degree of cross-linking, which affect longevity and stability; gel hardness, which helps determine flow properties, the extrusion force required, and the structure and stiffness of the finished product; and the degree of gel swelling, or ability to resist dilution, which also influences longevity.^{23,26,27}

Commercially available hyaluronic acid fillers differ in their specific properties, thus contributing to differences in their clinical applications and performance (Table 2).^{26,28–33} These differences allow clinicians to select the most appropriate agent for a given treatment need. For example, one important consideration is longevity of effect, and available dermal fillers offer a wide range of expected durations.³⁴ In addition, within the category of hyaluronic acid fillers, products differ in expected longevity, and recently, product labeling for the Juvéderm fillers (Allergan, Inc., Irvine, Calif.) was revised to note that the treatment effects last up to 12 months.³³ In the clinical experience of the faculty, various fillers differ from each other in their duration of effect.

Some investigators have expressed the opinion that permanent fillers may lead to longer-lasting complications that are difficult to treat.³⁵ They have noted that such agents may also lead to an aesthetically unsatisfactory outcome that cannot easily be corrected.^{34–36} Moreover, areas treated with such substances will not age in the same way as the rest of the face, with potentially unsatisfactory longer-term outcomes.^{34–36} Clinical studies on polymethylmethacrylate and bovine collagen have, however, indicated a relatively low rate of late-occurring adverse events.³⁷ In the current trials reported, late adverse reactions occurred in 2.2

percent of the wrinkles treated, of which two reactions were considered severe in one patient.

On balance, the participants in this conference considered that, at this time, temporary fillers such as hyaluronic acids afford clinicians and patients a long-lasting outcome (Table 2) without the risks associated with permanent fillers and their use can be repeated as needed to maintain a satisfactory outcome and address evolving treatment needs. Hyaluronic acid fillers have an excellent safety profile. Many complications can be avoided by careful injection technique or reversed by injection of hyaluronidase.³⁸ For patients desiring a more permanent effect, hyaluronic acid fillers can be used initially to provide the patient with an opportunity to evaluate the effects.³⁵

In summary, the use of minimally invasive products such as BoNTA and hyaluronic acid dermal fillers has expanded significantly from their original applications to encompass mobility restriction, volumizing, and contouring alone and in combination to manage the multidimensional aspects of facial aging (Table 3). Meaningful differences exist among botulinum toxin formulations and hyaluronic acid filler preparations, and practitioners should be familiar with these differences to achieve optimal outcomes.

Table 2. Comparisons among Selected Commercially Available Hyaluronic Acid Fillers

	Restylane, Perlane	Juvéderm Ultra (24 HV), Juvéderm Ultra Plus (30 HV)
Source	Bacterial fermentation	Bacterial fermentation
Gel-sizing process; product consistency	Sieving; granular	Homogenization; smooth
Cross-linking agent	BDDE	BDDE
HA concentration	20 mg/ml	24 mg/ml
Duration of effect (FDA label)	~6 months	~12 months

BDDE, 1,4-butanediol diglycidyl ether; HA, hyaluronic acid; FDA, U.S. Food and Drug Administration.

Table 3. Evolving Aesthetic Uses of Botulinum Toxin Type A and Hyaluronic Acid Fillers

Older treatment approaches

Restricting movement to smooth lines (BoNTA)

- Glabellar lines*
- Horizontal forehead lines
- Crow's feet
- Bunny lines
- "Chemical" brow lift

Filling lines and folds (HA)

- Nasolabial folds
- Lips (border and volume)

Newer treatment approaches

Restricting movement, volumizing, contouring

- Treating multiple areas of the face
- Using combinations of BoNTA and HA fillers (e.g., brow lifting and shaping)
- Expanding treatment of the lower face with BoNTA, especially in combination with HA filler
- Shaping the jaw line with HA filler
- Using BoNTA for masseter reduction
- Periorbital volumizing with HA filler
- Restoring malar projection with HA filler
- Preventing lines with BoNTA

BoNTA, botulinum toxin type A; HA, hyaluronic acid.

*Botox (Allergan, Inc., Irvine, Calif.) is indicated for temporary improvement in the appearance of moderate to severe glabellar lines associated with corrugator and/or procerus muscle activity in adult patients 65 years of age and older (from Allergan, Inc. Botox Cosmetic [package insert]. Irvine, Calif.: Allergan, Inc., 2005).

FACIAL AGING AND REJUVENATION

General Principles

Facial aging progresses as the result of both intrinsic and extrinsic contributing factors. Over time, loss of subcutaneous fat, gravitational changes due to loss of elasticity, and remodeling of bony and cartilaginous structures lead to visible signs of aging. All portions of the face do not age simultaneously. For example, it has been observed, and confirmed in studies, that the subcutaneous fat of the face exists as separate and distinct anatomical compartments that may age differently with respect to each other.³⁹ Similarly, the bony changes that occur may affect different parts of the facial skeleton differently. A recent study using computed tomography demonstrated that the skeleton of the midface below the inferior orbital rim undergoes significant changes while the anterior projection of the inferior orbital rim remains relatively fixed at its midpoint.⁴⁰

With age, repetitive muscle activity leads to fine lines that eventually become hyperdynamic wrinkles, which may deepen and ultimately remain apparent even when the muscles are at rest. Photodamage and smoking both accelerate these changes, with photoaging being the single most important contributor to the appearance of aging skin, including its texture and pigmentation.^{41,42} Due to the numerous factors contributing to the visible signs of aging, facial rejuvenation is likely to be best served by a multipronged approach.⁴³

Effects of Sex and Skin Color

In addition to environmental influences on aging, sex and skin color contribute to the manifestation of facial aging. Interestingly, although similar environmental factors affect perceived age among men and women, the strength of the association varies between the sexes. In a study of aging twins, for example, a history of smoking, sun exposure, and low body mass index were associated with higher perceived age in males. For fe-

males, significant determinants of high perceived age were low body mass index, sun exposure, smoking, and low social class.⁴⁴

In general, muscles of males tend to have a greater mass, which can affect the typical doses of BoNTA used in treatment.³ Other aspects of muscular anatomy, such as location and insertion point, may vary between individuals without being sex-specific, as indicated by a study of the anatomic position of the corrugator supercilii in cadavers.⁴⁵ When white males and females were compared within age groups, males tended to have consistently larger dimensions than females. The specifics of growth and aging of their soft tissue also differed, however, based on computerized three-dimensional mesh diagram analyses.⁴⁶ It has also been pointed out that the skin of males and females differs substantially, particularly with regard to thickness.⁴⁷ The effects of photoaging tend to be less pronounced in males than in females. Female skin is also generally more sensitive to irritants and allergens as well as to procedures and products used in their skin care.⁴⁷ Particularly important to treatment planning are sex differences in idealized concepts of facial attractiveness (Table 4),⁴¹ but many of these descriptions are traditionally based on Caucasian ideals, which do not universally apply.⁴⁸

Ethnic groups differ in their facial characteristics with respect to both color and underlying structural or architectural differences.⁴⁸ Some of the important and most obvious differences between skin of color and white skin are in melanosome type and size, distribution, and degree of melanization, which determines responses to ultraviolet radiation and thus, to some extent, the effect of photoaging. The darker the skin, the less vulnerable it is to ultraviolet damage.⁴⁹ Skin of color also tends to be thicker and more sebaceous and to have more abundant collagen.⁵⁰ Consequently, the signs of aging differ among persons of different skin colors and ethnic backgrounds. For

Table 4. Sex Differences in Facial Aesthetic Ideals*

The Idealized Female Face	The Idealized Male Face
<ul style="list-style-type: none"> ● Large, smooth forehead ● Smaller nose ● Arched or gull wing-shaped eyebrow ● Wide-set eyes for a larger look ● Prominent cheekbones ● Heart-shaped taper in lower face ● Smaller lower-to-upper face ratio than in males ● Full, vermilion lips 	<ul style="list-style-type: none"> ● Overhanging, horizontal brow ● Larger nose ● Minimal eyebrow arch ● Deeper-set eyes, appearing closer together ● Wider mouth ● Squared lower face ● More equal ratio of lower-to-upper face proportions ● Beard or coarser texture to lower facial skin

*Modified from Tan, S. R., and Glogau, R. G. Filler esthetics. In A. Carruthers and J. Carruthers (Eds.), *Procedures in Cosmetic Dermatology Series: Soft Tissue Augmentation*. Philadelphia, Pa.: Saunders, 2005.

example, darker and thicker skin is not prone to developing the fine lines associated with aging lighter skin types.^{50–52} Both Asian skin and darker skin types have a higher probability of pigmentary changes with aging as well as dyschromias in response to treatments.^{49,53}

Anthropometric studies conducted in various populations provide quantification of some of the differences among and within ethnic groups and demonstrate how far various populations diverge from Caucasian aesthetic ideals, which have traditionally driven much of facial plastic surgery.⁴⁸ Faculty members discussed the substantial differences in profiles of Asians, African Americans, and Caucasians and their effect on treatment planning.

In Asians, for example, the lips project more than the nose and chin, whereas in Caucasians, the nose and chin project more than the lips. With aging, the lips of Asian patients tend to deflate and become flatter. The treatment goal with filler is to restore volume but not to cause excess protrusion, and faculty members recommended that practitioners separate these two effects conceptually. Asian patients tend to object to a bulging in the lower periorbital area and benefit from small amounts (2 U) of BoNTA just below the inferior ciliary line (approximately 1 to 2 mm). This provides a rounder, more youthful look to the eyes. Note that BoNTA should not be injected into the medial lower lid, because excess weakness in the medial orbicularis oculi may produce epiphora from decreased muscular squeeze toward the canaliculus. These injections may also result in morning edema of the lower eyelid due to decreased squeeze of fluid into the lymphatics.

Adding treatment of the crow's feet and lateral brow can also help widen the appearance of the eye. In general, faculty members who treat Asian patients cautioned that BoNTA treatment should be conservative. They also noted that combination treatments with BoNTA and hyaluronic acid fillers may provide better results than monotherapy.

Facial aging in African Americans differs somewhat from that in Caucasians. For example, aging in the midface is prominent.⁵⁴ Faculty members who treat African Americans noted that these patients exhibit a significant loss of volume in the midface with age and have heavier cheeks, a prominent tear trough, and fewer fine lines and wrinkles than Caucasians. Treating only the nasolabial folds in patients with this type of presentation can result in a very unnatural look; in contrast, malar augmentation provides more satisfactory outcomes.

Clinical studies have demonstrated that both BoNTA and hyaluronic acid fillers are effective and well tolerated in persons of color.^{55,56} For example, in women of skin types V or VI, BoNTA (20 U, $n = 15$; or 30 U, $n = 16$) safely reduced the severity of glabellar lines, with a high level of subject satisfaction (100 percent at day 30) that lasted for the 4-month duration of the study in 60 percent of subjects.⁵⁵ In another study, the Juvéderm formulation of hyaluronic acid provided longer-lasting improvement in the appearance of nasolabial folds in both Caucasians and persons of color compared with bovine collagen.⁵⁶ No differences in efficacy based on skin type were observed throughout the 24-week duration of this study. No increased incidence of hyperpigmentation or hypertrophic scarring occurred in persons of color as compared with Caucasians, and there were no serious treatment-related adverse events. The incidence of adverse events did not differ by treatment or skin type. In clinical practice, faculty members recommend reducing the number of injections in persons of color to reduce the risk of hyperpigmentation.

As faculty members pointed out, treatment planning and goals must take each individual's presentation into account to provide a harmonious, balanced outcome. Ethnic background and skin type add another dimension to the evaluation: sensitivity and consideration of cultural and ethnic aesthetic ideals and goals, such as maintaining ethnic identification while improving appearance. This is, however, in keeping with an essential guiding principle of aesthetic treatment: tailoring treatment realistically to specific individual goals and needs, which plays an important role in determining timing and use of specific products and ensuring high patient satisfaction.

General Product Usage Considerations

Virtually all faculty members stated that they use a variety of products depending on needs, area of the face, patient preferences or request, and product characteristics. With hyaluronic acid fillers, for example, the choice is very dependent on patient presentation. Faculty members generally prefer softer gels for more superficial use and more robust or stiffer products for deeper use, but said that the type of skin may play a role in dictating choice of product. Faculty members noted that they view all fillers as falling along a continuum from softer to stiffer products. They also stressed the concepts of layering with different products and using enough product to provide

optimal outcomes. In their opinion, complications were in many instances a function of technique rather than solely a result of product characteristics. One important general way to reduce complications with filler injections is to slow the injection down and use finer-gauge needles (e.g., 30 g) that are longer than 1 inch in areas such as the infraorbital hollows. Faculty also recommended avoiding superficial use of stiffer products in areas such as the glabella, where they have the potential to compromise the capillary bed and lead to necrosis. In the experience of the faculty, these adjustments may help minimize swelling. Novice injectors need to understand that each product and syringe set has a different feel to it, that injection technique has to be adjusted for each product and treatment area, and that less may often be more.

TREATING THE UPPER FACE WITH BoNTA AND HYALURONIC ACID FILLERS

Aging Considerations in the Upper Face and Areas of Interest

Aging changes in the upper face reflect the effects of ultraviolet damage, gravitational changes, and muscles of facial expression on overlying skin.⁴² Although volume changes occur in parts of the upper face with age, they are not the most overtly apparent visible signs of aging in this region.

The muscles involved in upper facial expression and the central role of brow position have previously been reviewed.^{3,8} The hyperdynamic lines that form as a result of muscle activity are primarily perpendicular to the contraction direction of the muscles, but with aging, sleep creases also form on damaged skin. Loss of brow elevation is noticeable when the eyebrows descend below the level of the supraorbital ridge. Lateral brow ptosis also becomes apparent as temporal hooding. Overall, the appearance is one of fatigue and/or other negative expressions, such as anger, sadness, or disapproval, that are discordant with reality.

BoNTA has become the standard for nonsurgical upper facial rejuvenation. By reducing the motility of the muscles of facial expression, BoNTA significantly reduces the severity of upper facial rhytides and leads to a smoother, more youthful appearance. Another use of BoNTA in the upper face is to widen the eye. Injection of 2 U of BoNTA subdermally into the orbicularis oculi in the midpupillary line 3 mm below the ciliary margin increased palpebral aperture, especially

when combined with injections into the lateral canthus.⁵⁷ The authors noted that the outcome was most dramatic in Asian subjects. Moreover, by understanding the interplay of the elevator and depressor muscles of the upper face, clinicians can use BoNTA for managing asymmetries and repositioning, such as eyebrow lifting.^{1,3,58–63}

Literature Update on the Upper Face

Much of the literature on the use of BoNTA to treat the upper face has focused on line effacement in single facial areas, but in clinical practice, it is common to treat more than one area. One recent placebo-controlled, double-blind study examined the efficacy and safety of treating the forehead, glabellar area, and crow's feet in a single session.⁹ In this study, female subjects received 64 U of BoNTA divided equally among 16 sites in the glabella (five sites), crow's feet (three sites per side), and forehead (five sites). The Facial Line Outcomes questionnaire was the primary outcome measure on which subjects rated items of importance to their appearance based on their previous 7 days' experience. Subjects also rated their perceived age of appearance using the single-item Self-Perception of Age. Facial Line Outcomes scores improved significantly after BoNTA but not placebo treatment, and were maintained through the duration of the double-blind period of 12 weeks. In addition, the number of subjects who reported looking younger than their current age increased from 35 percent at baseline to 75 percent at week 4; this was also maintained through week 12. Self-Perception of Age scores did not change with placebo treatment. During the study, no ptosis occurred and any adverse events were transient and mild to moderate in severity. This study confirmed widespread clinical experience that BoNTA can be used safely and effectively to treat multiple areas of the upper face in a single session.

Of increasing interest is the addition of hyaluronic acid filler to BoNTA to expand the options when treating the upper face.^{1,8,64} The results of a prospective, randomized study of BoNTA in combination with hyaluronic acid filler demonstrated that combination treatment of glabellar rhytides improved outcomes in comparison with hyaluronic acid filler alone.⁶⁵ In this study, female subjects with deep resting glabellar rhytides received hyaluronic acid filler either alone ($n = 19$) or in combination with BoNTA ($n = 19$). BoNTA (30 U) was injected 1 week before hyaluronic acid filler was used in those receiving combination

treatment.⁶⁵ Combination treatment nearly doubled the median duration of response compared with treatment with filler alone.⁶⁵ In addition to increasing durability of outcome, combination treatment also increased the percentage of subjects with aesthetic improvement at week 16 (95 percent versus 83 percent). At both rest (through week 32) and maximum attempted contraction (through week 16), responder rates were significantly greater with combination treatment. This study did not include a BoNTA-only arm, so the effect of BoNTA alone compared with combination treatment cannot be assessed from this study.

Consensus Recommendations

What Has Changed?

Many of the changes that have taken place in approaches to facial rejuvenation have come about because of increased understanding of facial aging, expansion in the numbers and types of products available, and associated refinements in aesthetic goals—specifically, providing a balanced, harmonious, and natural look.

Consensus recommendations on use of the Botox formulation of BoNTA alone have previously been published (Table 5).³ Changes from these original recommendations, based on this current update, are also shown in Table 5. Most importantly, 100 percent of the faculty agreed that they have decreased the number of units of BoNTA they used to treat the forehead.

Changes from Previous Recommendations

To treat horizontal forehead lines in female patients, 57 percent use 6 to 10 U and 43 percent use 11 to 15 U, compared with the typical dose of

15 U previously recommended. For male patients, 73 percent use 11 to 15 U, with the remainder of the faculty evenly divided between higher and lower doses. Previously, the typical range for male patients was 20 to 30 U. Interestingly, the faculty now use somewhat higher amounts of BoNTA to treat crow's feet in men.

Current Practice in the Upper Face: Staging of Treatment

For the glabellar area, BoNTA is used alone about 75 percent of the time; when it is used in combination with fillers, 73 percent of the faculty noted that they stage the treatments for new patients, treating first with BoNTA and then with filler. This allows for the assessment of residual static lines/folds after BoNTA has taken effect. A minority of the faculty sometimes treat with both BoNTA and filler during a single treatment session. Approximately 43 percent of the faculty split the treatment of the glabella and frontalis into two visits when treating a patient for the first time.

Combination versus Single Treatment

Presently, all of the faculty use BoNTA alone to shape the brow about 50 percent of the time, but more than 90 percent of the faculty also use filler in some patients to replace volume in the brow area. Combination treatment of BoNTA and filler is used in the brow area about 20 percent of the time. Approximately 67 percent of the faculty use filler alone to fill the expression folds of the lateral frontalis immediately above the lateral upper brow of some patients. All faculty members continue to treat crow's feet with BoNTA, but 80 percent now use it in combination with filler for some patients as part of treatments to enhance malar volume (see Treating the Midface with

Table 5. Consensus Recommendations on the Use of Botulinum Toxin Type A* in the Upper Face†

Region/Target Muscle(s)	Usual No. of Injection Points (range): Unchanged from Original Recommendations	Total Starting Dose: Usual Range	
		Original Recommendations	Revised Recommendations
Glabellar complex (procerus, depressor supercilii, orbicularis oculi)	5 to 7; men may require more sites	Women: 20 to 30 U; men: 30 to 40 U	Women: 10 to 30 U; men: 20 to 40 U
Horizontal forehead lines (frontalis, but consider interactions with procerus, corrugators, and orbicularis oculi in overall facial shape)	4 to 8; more or fewer may be required based on anatomic and aesthetic evaluations	Women: 15 U, 10 to 20 U; men: 20 to 30 U	Women: 6 to 15 U; men: 6 to >15 U
Crow's feet (lateral portions of the lateral orbicularis)	2 to 5 per side (higher in selected patients)	12 to 30 U	Women: 10 to 30 U; men: 20 to 30 U

*BoNTA injection sites and volumes are for the Botox formulation.

†Adapted and updated from Carruthers, J., Fagien, S., Matarasso, S. L., et al. Consensus recommendations on the use of botulinum toxin type A in facial aesthetics. *Plast. Reconstr. Surg.* 114 (Suppl.): 1S, 2004.

BoNTA and Hyaluronic Acid Fillers). In treating the upper face, faculty members agreed that restoring volume in the temporal region is an emerging treatment area. Faculty reported using a variety of different fillers in this area.

Order of Treatment When Treating Multiple Upper Facial Areas

When treating multiple areas of the upper face, 47 percent of the faculty treat the glabellar area first, followed by the forehead and then the crow's feet. Another 47 percent of the faculty treat crow's feet first, followed by the glabellar lines and then the forehead. All faculty noted that the most important consideration of the order is to track the treatments that have been performed in terms of injection location and units.

Using Hyaluronic Acid Fillers in the Upper Face

Most participants in the consensus meeting reported using more than one product, depending on the specific need. Use of hyaluronic acid fillers was divided evenly among Restylane, Juvéderm Ultra, and Juvéderm Ultra Plus. The usual amount of hyaluronic acid filler varied by site and ranged from 0.1 ml to 1.0 ml. About 50 percent of the faculty use 0.5 ml or less per site. Specific recommendations for hyaluronic acid filler use in areas of the upper face are listed in Table 6. The faculty noted that loss of volume in the temple area lateral to the tail of the eyebrow is associated with a drop in the tail of the brow. By using filler in the temple area and under the lateral brow and a small amount of BoNTA in the tail of the brow, a very attractive effect can be obtained. Patients may be unaware of the potential for treating this area with combination treatment and may need to be educated about it.

Avoiding and Managing Complications in the Upper Face

The most common complications with BoNTA are an overtreated frontalis, dropped brow, asym-

metry, and bruising, particularly in the lateral canthus. Understanding the anatomy and evaluating each patient under dynamic and resting conditions can help avoid these complications. Patients with a low brow or evidence of pre-existing ptosis should be evaluated carefully before treatment. Eyebrow ptosis can generally be avoided by injecting no closer than 1 cm above the bony orbital rim in the midpupillary line and using lower doses in the frontalis. Faculty members recommended decreasing the amount of BoNTA used in treating older patients to avoid brow ptosis when trying to elevate the forehead. Many patients may require education about the need for striking a balance between reducing the appearance of forehead lines and the risk of brow ptosis. All patients should be counseled not to manipulate the treated area for several hours after treatment.^{3,66}

Injecting the medial aspect of frontalis fibers with BoNTA, without treating the lateral frontalis fibers, can result in a cocked eyebrow in some patients. This can be corrected by injecting 1 to 3 U of BoNTA into untreated fibers that are causing the upward pull.⁶⁷ Note also that these recommendations are only for the Botox formulation of BoNTA. Various lines of research, as well as the clinical experience of the faculty, indicate that another formulation of BoNTA (Dysport) exhibits a greater tendency to diffuse from the site of injection, which would be of clinical relevance in the small muscles of the face.^{16,68,69}

Conference participants agreed that using hyaluronic acid or any other dermal filler in the upper face, particularly the glabella, is an advanced technique that should be undertaken only by very experienced injectors. Although rare, the most serious potential complication is necrosis, which can occur most commonly when any filler is injected intravascularly (Table 7).^{24,35,67,70} Injectors should have thorough knowledge of the anatomy and blood supply of the area and must be alert to blanching or sud-

Table 6. Recommendations for Use of Hyaluronic Acid Fillers in the Upper Face

Treated Area	Filler Volume	Comment
Glabella	<0.25 ml in most patients; up to 0.5 ml	Stay superficial to mid-dermis, and aspirate if necessary; avoid compressing vessels
Forehead	Depends on length of rhytide and degree of compensation; dictated by product to be used	Use softer products and avoid hard products that bead
Crow's feet	0.25 ml	Avoid stiff fillers, and proceed gradually and with caution; place hyaluronic acid fillers deeper than soft collagen
Bunny lines	~0.10 ml	Use soft, malleable product

Table 7. Managing Potential Complications with Hyaluronic Acid Filler Treatments in the Upper Face

Potential Complications	Management Approach
Necrosis	<ul style="list-style-type: none"> ● Use caution to avoid injecting intravascularly; inject slowly (<0.3 ml/min) and with low pressure; watch for danger signs, such as sudden pain or blanching ● Use a topical vasodilator immediately; inject hyaluronidase for hyaluronic acid fillers ● Use low-molecular-weight heparin daily for 1 week^{*24,35,67,70}
Beading, clumping, overcorrection	<ul style="list-style-type: none"> ● Avoid overcorrection in initial injection by using multiple puncture serial technique; consider smaller-gauge needles to control amount of filler injected ● Massage to distribute filler; use less in future ● Use hyaluronidase to reverse unwanted effects of hyaluronic acid filler

*Evaluate risks associated with heparin treatment when considering its use.

den pain, which can indicate blood vessel occlusion or compression.

Summary Recommendations and Key Insights for Treating the Upper Face

BoNTA remains the main treatment option for the upper face, but dermal fillers such as hyaluronic acid are being added to the armamentarium to augment the results achieved by BoNTA alone. Also, doses of BoNTA, particularly in the forehead, are definitely lower than previously recommended to maintain some muscle movement, to minimize adverse outcomes such as brow ptosis, and to maintain a more harmonious aesthetic appearance. Doses of BoNTA greater than 20 U in the frontalis are more likely to lead to suboptimal outcomes. All faculty agreed that a frozen look is not a desirable goal, even though some patients expect to have a high level of immobility. In those cases, patient education is very important, to establish realistic and aesthetically pleasing expectations.

Combination treatment may increase the longevity of the outcomes.⁶⁵ The consensus of the faculty was that BoNTA treatment should generally be performed first to assess the need for treatment of residual issues, such as static lines and deep folds that can be treated with hyaluronic acid fillers. It is now recognized that shaping of the brow region is a three-dimensional challenge that is well suited to the use of both BoNTA and hyaluronic acid fillers used in the superior orbital rim, especially in the lateral brow. An emerging use for fillers is to address the aging-related loss of volume in the temples. In all cases, it is important to consider patients' sex and ethnic differences and to keep balance in mind when treating the upper face (e.g., relaxing the frontalis versus the degree of brow ptosis or change in the shape or arc of the brow). Some of these techniques, particularly the use of dermal fillers, should be reserved for use

by experienced injectors because of the risk of blood vessel occlusion or compression.

TREATING THE MIDFACE WITH BoNTA AND HYALURONIC ACID FILLERS

Aging Considerations in the Midface and Areas of Interest

An important contributor to aging changes in the midface is the remodeling of underlying cartilaginous and bony structures that occurs, in addition to photodamage and loss of subcutaneous tissue and cutaneous elasticity.^{40,41} Changes in the structure of and relationships between the inferior orbital rim and the anterior maxilla markedly influence facial appearance, including the appearance of the eyes.⁴⁰ The key to rejuvenating the midfacial area is volume restoration through re-inflation and recontouring. The specific areas of interest are the malar smile lines, malar projection, infraorbital hollow (arcus marginalis), nasojugal fold (tear trough, which is the medial arcus marginalis), nasolabial folds, and nasal dorsum and tip (Fig. 1). Each of these areas is considered below.

Literature Update on the Midface

Clinical experience using BoNTA and/or dermal fillers to treat various midfacial areas has been reported and reviewed.^{1,8,71} Several clinical studies and case reports document techniques and outcomes for treating midfacial sites with hyaluronic acid filler. For example, a technique of nonsurgical lower eyelid lift performed by filling the hollows with hyaluronic acid has been described, with the total filler volume reported as ranging from 0.35 ml to 1.40 ml per side, injected in small amounts.⁷² These investigators cautioned injectors to avoid the infraorbital nerve and periorbital arteries.

In another study, 24 female patients received hyaluronic acid filler to treat tear troughs.⁷³ The filler volume ranged from 0.1 to 0.45 ml per eyelid,

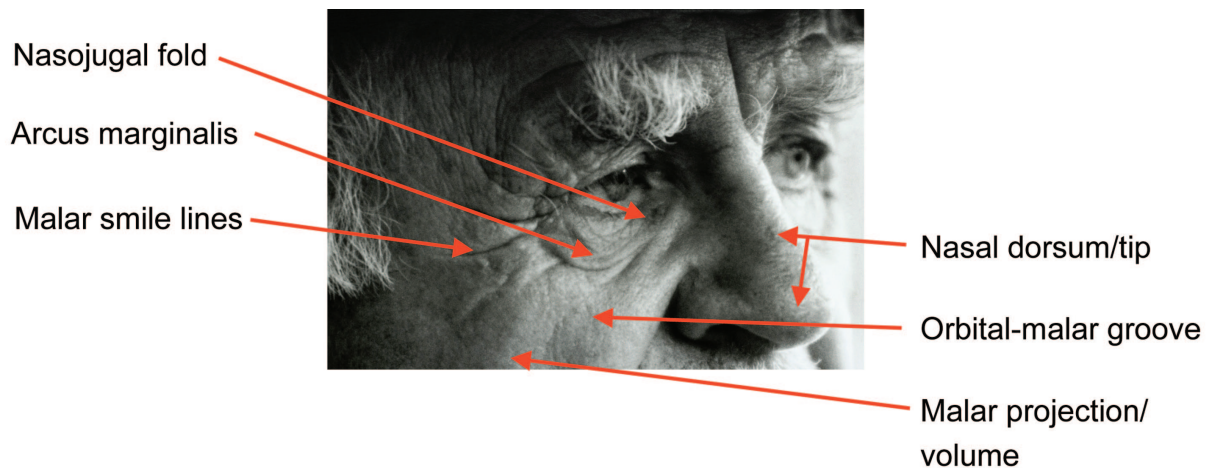

Fig. 1. Changes in the midface due to aging.

with most patients requiring 0.2 to 0.3 ml. The deepest portion of the medial tear trough was treated first, and multiple passes with small amounts of hyaluronic acid filler were used. At the 10-day follow-up, 22 of the patients reported satisfaction with their appearance.

A larger, retrospective analysis reported on 121 patients who had received hyaluronic acid treatments for periorbital hollows that included the orbital rim hollow, zygomatic hollow, septal confluence hollow, and cheek pad (as well as the eyebrow area).⁷⁴ The mean filler volume used to treat the orbital complex was 0.9 ml, and reinjection for maintenance was typically at about 6.5 months. Patient satisfaction was generally high: 86 percent were satisfied after the first injection, 91 percent after the second, and 100 percent after the third. Side effects were mild and transient and included color change, fluid build-up, lumpy or irregular contours, and bruising.

The basis for approving hyaluronic acid fillers for dermatologic use was their utility in treating nasolabial folds. In a multicenter, randomized, comparative study of 137 subjects, the Restylane formulation of hyaluronic acid provided a more durable response at 6 months than did bovine collagen, based on both physician and patient ratings.⁷⁵ Similarly, a multicenter, randomized study of Juvéderm fillers compared with bovine collagen in 439 subjects demonstrated that Juvéderm hyaluronic acid fillers provided a significantly longer duration of effect than did collagen.⁷⁶ Subjects also significantly preferred the Juvéderm treatments to the collagen treatments. Recently, approval was granted by the U.S. Food and Drug Administration to amend the labeling for Juvéderm Ultra and Juvéderm Ultra Plus to include the information

that the results of treatment with these products have been shown to last to up to 1 year.³³

Consensus Recommendations

General Principles

All faculty members agreed that one of the most important treatment considerations for the midface is the degree of volume depletion and flattening that occurs in the malar area. Accordingly, 60 percent of the faculty use fillers first followed by BoNTA treatment when a combination approach is indicated, to assess residual volume deficits, lines, and folds. They noted that not all areas of the midface are amenable to combination treatment.

Faculty members agreed that the malar contour should be restored first, followed by the orbital-malar groove and the nasojugal fold, which they noted to be the most complicated. When malar contour is restored, it results in a lift of the face and diminution of the nasolabial folds, affecting how the folds are to be treated. This approach, moreover, sometimes negates the need to treat the nasojugal fold/tear trough, which is a more complicated procedure. Thus, this conservative approach is a very useful way to begin treatment of the midfacial area.

Regarding injection technique, 56 percent reported using an anterograde technique. It is common to use the anterograde technique along the vermilion border, where the material will run along the potential tissue space with little or no additional movement of the needle tip. This can help verify the proper depth of placement for the needle tip. Other advantages of an anterograde approach is that it may yield a softer forward move-

ment through tissues, blunting the impact of the sharp needle tip, pushing vessels out of the way of the advancing needle, and reducing the probability of bruising. It is also possible to inject a small amount of hyaluronic acid filler moving forward to blunt the dissection and to inject additional filler as the needle is withdrawn if a greater volume of correction is needed. Those who prefer the retrograde injection technique believe that injecting slowly as the needle is withdrawn helps avoid intravascular injection of filler. This technique is often chosen for very soft, thin, or vascular areas, such as below the eyes or the malar region. In these areas, it is especially important to avoid tissue trauma; with a fine needle, it is thought that when the material flows as the needle is withdrawn, additional tracks or dissection planes are not created. This may be preferred when injecting areas with named vessels. Regardless of the technique used, it is essential to inject slowly (<0.3 ml per minute) and gently to avoid tissue tears.

Specific Recommendations by Treatment Area

Although it is a key principle to tailor treatment to each patient's specific presentation, recommendations were undertaken for a typical or average patient, a Caucasian woman approximately 45 years of age (Fig. 2). Filler volumes and treatment recommendations are listed in Table 8. Note that greater or lesser volumes may be suitable for individual patients, depending on their presentation. The recommendations in Table 8 are

generally conservative. For treating small malar smile lines, all of the faculty members use hyaluronic acid filler, but none uses BoNTA alone because of the risk of a stroke-like appearance and/or an inability to smile. Fewer than 20 percent use combination treatment in this area. To restore malar projection, faculty use a number of products: 100 percent use Restylane or Juvéderm Ultra Plus in some of their patients; another 25 percent use Juvéderm Ultra for some patients, depending on needs and goals. For this use, filler may be injected submuscularly as well as subdermally, particularly when using Perlane or Juvéderm Ultra Plus.

In treating the nasojugal groove, 67 percent of the faculty use Juvéderm Ultra and the remainder use Restylane. For nasolabial folds, treatment of the infraorbital hollow should be undertaken only by experienced injectors, with precautions to avoid injecting deep to the orbital septum. Although not a major application of fillers, a variety of products are also used to recontour the nasal dorsum and tip due to surgical depression or atrophic changes caused by aging: 44 percent of the faculty use Restylane, 25 percent use Juvéderm Ultra, 19 percent use Juvéderm Ultra Plus, and 50 percent also use fillers other than hyaluronic acid, such as calcium hydroxylapatite. Fewer than 10 percent use collagen in this area. Most of the faculty elevate the nose saddle, recontour the nasal tip, and inject filler at the base of the columella to lift the nasal tip as a whole. Asian patients may

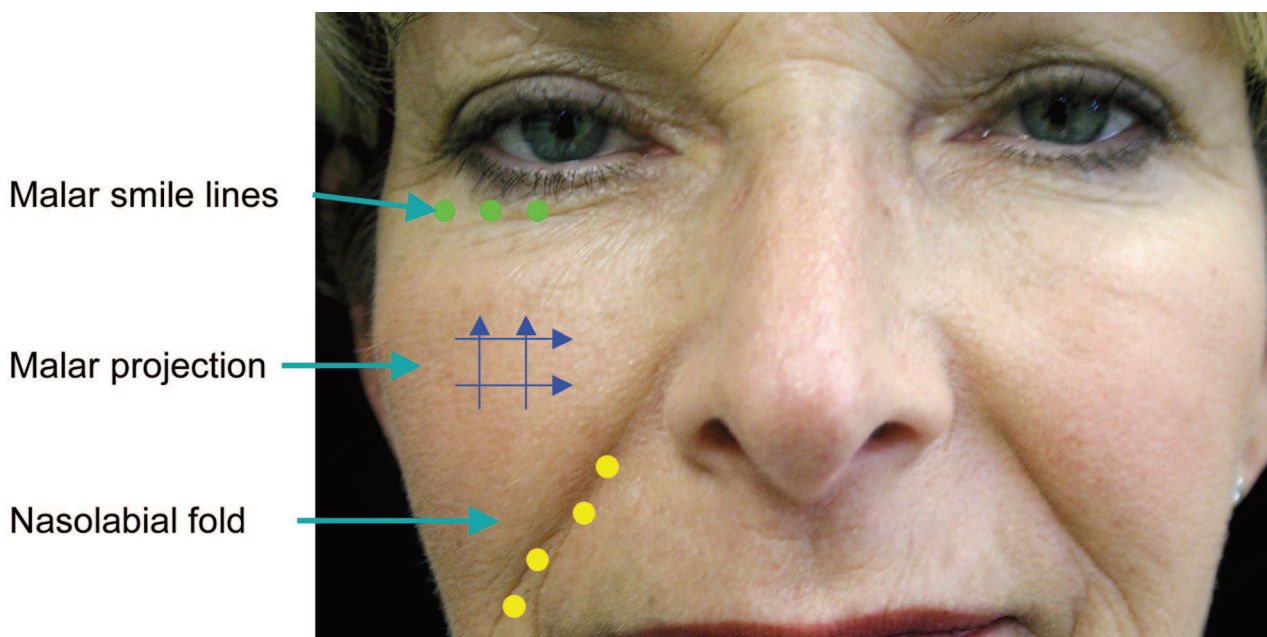


Fig. 2. Commonly treated areas of the midface. Injection sites and patterning for hyaluronic acid fillers are shown.

Table 8. Recommendations for Treating the Midface with Botulinum Toxin Type A* and Hyaluronic Acid Fillers

Treated Area	Filler Volume (% of faculty)	Comment
Malar smile lines	0.2 to 0.4 ml/side	Use deep dermal or subdermal injections and treat conservatively; may combine with resurfacing approaches or very small amounts of BoNTA; layering with different products can be used to address the etched-in superficial lines
Infraorbital hollow (arcus marginalis)	0.2 to 0.5 ml/side	Undercorrect in this area; do not inject deep to the orbital septum; this should be attempted only by experienced injectors
Nasojugal fold (tear trough)	0.1 to 0.2 ml/side (80%), 0.25 to 0.4 ml/ side (20%)	Treat conservatively and re-evaluate need for additional treatment in 2 to 4 weeks; this should be attempted only by experienced injectors
Nasolabial folds	0.5 to 1.0 ml/side (81%), 1.1 to 1.5 ml/ side (19%)	Visualize the nasolabial folds as a triangular area to be filled rather than as a linear area; hyaluronic acid fillers can be layered with collagen or with each other; massage to distribute and contour fillers and reduce beading/clumping
Nasal dorsum and tip	≤0.5 ml	Can be used after rhinoplasty for refinement or to treat drooping that occurs with aging; BoNTA has been used to treat this area ⁷⁷

*BoNTA injection sites and volumes are for the Botox formulation.

benefit from small amounts of filler in the bridge of the nose, which may also soften the appearance of the epicanthal folds. Some faculty elevate the nasal tip by injecting 3 U of BoNTA into the nasal spine area and 5 U each into the lower nasalis.⁷⁷

Avoiding and Managing Complications in the Midface

General precautions are the same as for other areas of the face, such as using slow, gentle injections to prevent tissue damage while maintaining steady pressure on the plunger when advancing.

Precautions for treating the midface include the following:

- Avoid using BoNTA in the malar smile lines, to avoid causing a transient stroke-like, frozen appearance or an inability to smile
- Start conservatively with filler to avoid overcorrecting; touch-ups can be performed at follow-up visits in 2 to 4 weeks
- To achieve an optimal aesthetic and avoid clumping, massage filler to distribute it and to permit evaluation of the effect before treating other areas
- Do not inject deeply into the nasal septum
- Do not overfill the nasal area; treat conservatively and re-evaluate and re-treat if necessary

Summary Recommendations and Key Insights for Treating the Midface

The main focus of treatment of the midface is on volume restoration, which dictates that filler use predominate and that BoNTA, if used, play a more limited role. One of the potential first steps is to restore malar projection or volume, which

may obviate or modify treatment needs in other areas, such as the tear trough and nasolabial folds. After this, it is important to re-evaluate the remainder of the face and then treat. In treating the midface, it is important not to stint on filler volume, which may require educating patients to understand that undertreatment will yield suboptimal results.

Faculty members suggested marking each side of the face before injecting, which may help treatment of the second side if and when the first swells. Another option is to have the pretreatment photograph(s) available for comparison once the first side of the face undergoes augmentation. It was also suggested that clinicians use half the syringe, and then walk around to the other side of the patient to inject the other side of the face.

TREATING THE LOWER FACE WITH BoNTA AND HYALURONIC ACID FILLERS

Aging Considerations in the Lower Face and Areas of Interest

Aging changes due to photodamage, loss of subcutaneous fat, gravitational changes, and remodeling of the underlying bony and cartilaginous structures are very visible in the lips and surrounding tissues (Fig. 3).⁴¹ The appearance of the lower face is also modified by aging changes in the midface. In addition, dentition changes, resorption of mandibular and maxillary bone, forward rotation and protrusion of the chin, and other aging changes alter the proportions of the lower third of the face relative to the upper two thirds. Gravitational changes result in sagging skin, jowls, and wattles as well. Repeated muscular

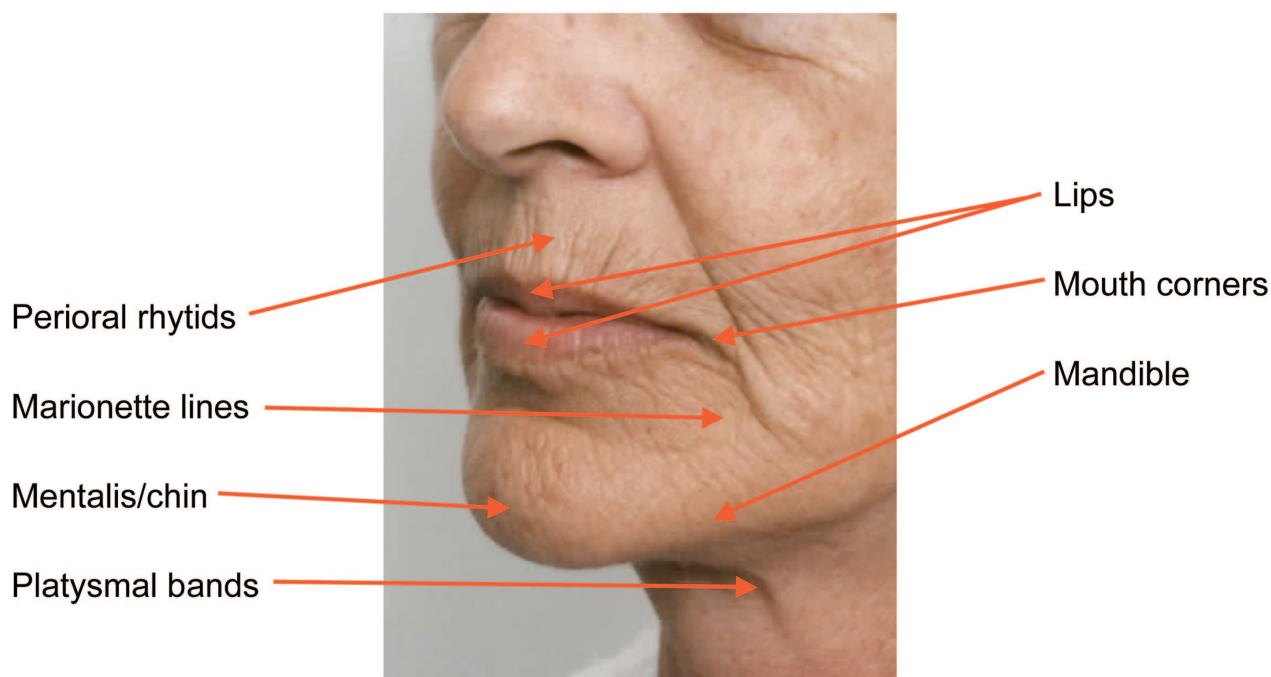

Fig. 3. Changes in the lower face due to aging.

contractions lead to furrows and lines that are superimposed on volume loss and exacerbated by loss of elasticity. Textural changes are also very apparent in the skin of the lower face, which may be amenable to various resurfacing modalities in combination with other treatments.

The orbicularis oris exerts a constant pull on the upper and lower lips that ultimately contributes to the formation of outwardly radiating perioral lines, sometimes called lipstick lines. Downward radiating lines, called marionette lines, form from the oral commissures due to the actions of the depressor anguli oris. The lips flatten and lose fullness, vertical height may increase, and the vermilion area may be reduced. As a result, the amount of dental display may be diminished and the Cupid's bow may also flatten.⁴¹ Loss of definition occurs around the mandible, and the mentalis area develops a pebbled appearance called *peau d'orange*, which results from mentalis activity over time in conjunction with volume loss in the chin.⁷⁸ Horizontal (necklace) lines form on the neck, and the platysmal bands become more prominent as elasticity is lost with aging.⁷⁸

In treating the lower face, the primary goals are to restore volume, reduce mobility, and resurface where appropriate. Faculty members consider combination treatment to be the standard for rejuvenating the lower face.

Consensus Recommendations

General Principles

The lips are the aesthetic focal point of the lower face. In treating the lips, 100 percent of the faculty use filler to shape the vermilion border and to volumize the lips. Approximately 50 percent each use collagen or hyaluronic acid filler routinely to enhance the vermilion border, and 100 percent use hyaluronic acid filler for volumizing the lips themselves.

For other areas of the lower face, including the depressor anguli oris, prejowl sulcus, mouth corners, and marionette lines, faculty members use BoNTA alone about 25 percent of the time, combination treatment about 50 percent of the time, and filler alone about 25 percent of the time. Some individual faculty members use combination treatment approximately 75 percent of the time. When combinations of BoNTA and filler are used, 87 percent of the participants treat with filler first. Treatments do not have to take place in a single session. One of the benefits of multiple sessions is the opportunity to reassess needs. All faculty members treat platysmal bands with BoNTA, and about 27 percent treat horizontal neck lines with BoNTA. Some practitioners also use hyaluronic acid fillers to manage the horizontal neck lines. They cautioned about the risk of hyperpigmentation when treating horizontal neck

lines in persons of color. As in other areas of the face, participants use a variety of different hyaluronic acid fillers to treat the lower face.

Specific Recommendations by Treatment Area

Area

The use of BoNTA alone in treating areas of the lower face has previously been detailed.³ In contrast to previous recommendations, the faculty members have tended to reduce the number of BoNTA units for each area treated (Table 8). An important use of BoNTA in the lower face is to treat asymmetrical smiles. It was emphasized that skin landmarks can be used in conjunction with identifying musculature, but not in place of it. The depressor anguli oris can be palpated, and the medial aspects should be avoided. Injecting too high will affect the orbicularis oris and can worsen asymmetry. One tip is not to go higher than halfway between the lip and the mandible.

Participants reported less variability in their treatments than they did previously. In particular, note the substantially lower number of units used to treat platysmal bands so as not to weaken the muscles of the neck. Combination treatment is emerging as the standard for treating the lower face.

In using fillers to treat the lower face, faculty members tend to view the area as a whole rather than as isolated regions (Fig. 4). When treating the vermilion border with hyaluronic acid filler, approximately 80 percent of the faculty use Juvéderm Ultra and the remaining use Restylane. For

volumizing the lips, Juvéderm Ultra, Juvéderm Ultra Plus, and Restylane are preferred by 44 percent, 31 percent, and 25 percent of the faculty, respectively. For volume enhancement of the lips and shaping the vermilion border, 67 percent of the faculty use 1.0 ml of hyaluronic acid filler. The remaining 33 percent use 2.0 ml. The faculty cautioned about overfilling the lips and creating excessive protrusion (“duck lips”). It is important to think of shaping the lips, not simply adding volume. For example, when patients request an increase in the vertical height of the vermilion, it must be realized that filler is also going to increase the lips circumferentially. Rebuilding the philtral columns can be effective but must be done conservatively to avoid asymmetry.

For marionette lines (melomental folds) and the prejowl sulcus, 56 percent of the faculty use one syringe of hyaluronic acid filler and the remaining 44 percent use two syringes. Again it was stressed that using an adequate volume of filler is a key determinant of a successful outcome and patient satisfaction. Patients are apt to require education about the potential benefits and limitations of treatment, including the likelihood of suboptimal outcomes if an insufficient volume of filler is used.

Managing Complications in the Lower Face

The previous consensus conference reviewed potential complications with BoNTA in detail.³ In

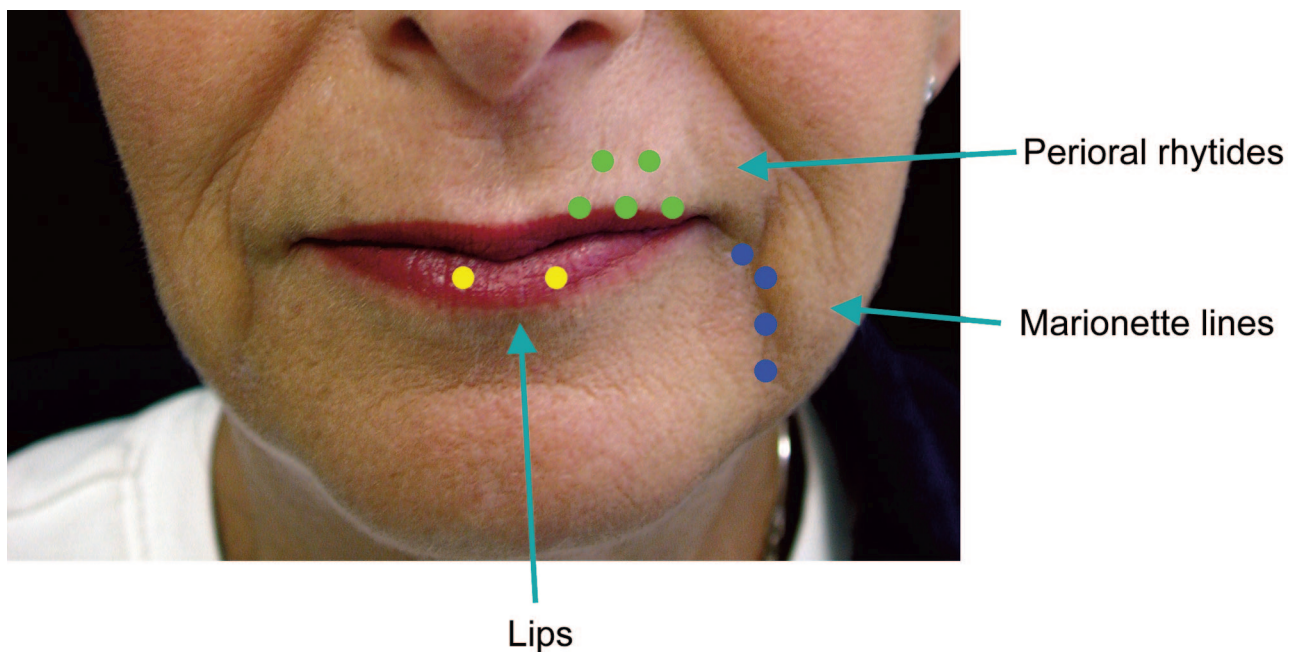


Fig. 4. Commonly treated areas of the lower face. Injection sites and patterning for hyaluronic acid fillers are shown.

the update meeting, faculty members reiterated the critical importance of understanding the anatomy in the lower face and using that, rather than skin landmarks, to direct injection sites. In treating the perioral area with BoNTA, the main precautions are to avoid overtreatment or injecting too close to the mouth, in order to prevent mouth incompetence, drooling, speech problems, and diminished proprioception (Table 9).³

Clinicians should begin conservatively and re-treat at a follow-up visit if necessary. In the first meeting, consensus panel members recommended that injections always be symmetrical and that the midline be avoided to prevent additional flattening. In the update meeting, it was noted that it is sometimes desirable to treat the lower lip area at the same time as the upper lip area to aid in proprioception. When treating the mentalis with BoNTA, it is important to avoid the depressor labii and consequent risk of lower lip depression. Again, injecting too close to the mouth may result in lower lip incompetence and drooling.³

Faculty members suggested that using higher dilutions of BoNTA coupled with more injection points could help avoid asymmetries of the upper lip, some of which result from unequal innervation by the depressor anguli oris. They also noted that injections of BoNTA into the platysma that are too high up on the neck can result in lip asymmetries. For hyaluronic acid fillers, careful injection planning to deliver equal amounts to each side of the face is important in avoiding asymmetries.

The platysma is a very superficial muscle, and injecting BoNTA too deeply in the platysmal bands may affect the strap muscles, causing dys-

phagia, or the cricothyroid muscle, leading to voice changes.^{78,79} It was noted that injecting the pars facialis just below the mandibular margin is safe, and that a danger zone is just at the cervicomental junction because of subjacent muscles involved in swallowing. Complications can be avoided by carefully marking the areas to be injected, injecting only the bands that can be grasped, and/or by using electromyographic guidance if necessary.⁷⁹ In some instances, the reversible, orally active anticholinesterase agent pyridostigmine may be used (60 mg) to counteract some of the effects of BoNTA (J. C. Carruthers, personal experience). This use of pyridostigmine, however, should be balanced against the risk of potential side effects, such as nausea, vomiting, diarrhea, and increased salivation, and pyridostigmine should not be considered for routine administration.⁸⁰ For hyaluronic acid fillers, careful injection planning to deliver equal amounts to each side of the face is important to avoid treatment-induced asymmetries.

Summary Recommendations and Key Insights for Treating the Lower Face

Full rejuvenation of the lower face involves the control of muscle movement as well as the restoration of volume. In many cases, neither BoNTA nor hyaluronic acid filler alone will provide optimal results. It is critical to know the musculature and its complex interactions in this area. Poor treatment planning and reliance on skin landmarks may lead to asymmetries and other suboptimal outcomes. Faculty members stressed that many patients complain about the appearance of

Table 9. Consensus Recommendations on the Use of Botulinum Toxin Type A* in the Lower Face†

Region/Target Muscle(s)	Usual No. of Injection Points (range)	Total Starting Dose: Usual Range	
		Original Recommendations	Revised Recommendations (% of faculty)
Perioral area, orbicularis oris	2 to 6; to start: 4 sites, 1 site per lip quadrant	4 to 10 U evenly divided among sites	4 to 5 U (75%) Note: treat lower lip in same session
Dimpled chin (peau d'orange), mentalis	1 to 2 (start with 1 midline or 2 symmetrical, lateral injections)	Women: 2 to 6 U; men: 2 to 8 U	4 to 5 U (56%); 6 to 10 U (44%)
Neck, platysmal bands, platysma	Women: 2 to 12 per band; men: 3 to 12 per band	Women: 10 to 30 U; men: 10 to 40 U	≤10 U/band (73%); 11 to 20 U/band (27%); 40 to 60 U total per neck per treatment session

*BoNTA injection sites and volumes are for the Botox formulation.

†Adapted and updated from Carruthers, J., Fagien, S., Matarasso, S. L., et al. Consensus recommendations on the use of botulinum toxin type A in facial aesthetics. *Plast. Reconstr. Surg.* 114 (Suppl.): 1S, 2004.

their lips, and a substantial degree of education may be needed to help them understand the value of treating the entire lower facial region. In general, the perioral area should be managed conservatively, with follow-up visits scheduled to assess the need for additional treatment. The faculty cautioned against the use of high doses of BoNTA (>50 to 75 U per treatment session) in the platysmal bands because of experience with dysphagia and the need for treatment with a nasogastric tube.

OTHER ADVANCED TECHNIQUES AND EMERGING TRENDS

New and expanding uses for both BoNTA and hyaluronic acid filler continue to emerge rapidly. The faculty members discussed some of the most important techniques, based on their experience and the published literature. They also discussed the most prevalent trends in facial rejuvenation that they are observing in the literature and in clinical practice.

Acne and Other Scars

The faculty agreed that the use of either BoNTA or hyaluronic acid filler for acne scarring is still undergoing investigation. They pointed out that scars differ and that no one treatment is suitable for all. It was also noted that active inflammation is a contraindication to hyaluronic acid filler use and that BoNTA should not be used in infected sites.^{14,28,31} None of the participants use BoNTA alone to treat scars, whereas all have used hyaluronic acid filler alone. For long-standing, atrophic scars, small volumes of hyaluronic acid filler can be used to soften the appearance. Also, scar appearance may worsen with age, and hyaluronic acid fillers can be used to augment the volume of the area and thereby improve appearance. Repeated treatments may be necessary to provide optimal correction. All faculty members agreed that fractional resurfacing technology is an excellent approach to acne scarring.

Chin Implants

Hyaluronic acid fillers are useful in smoothing the appearance of chin implants, particularly in the transition area between the implant and soft tissue. In addition, the skin over the chin implant may dimple, which can be addressed by injecting approximately 8 to 10 U of BoNTA into the mentalis.

Horizontal Upper Lip Line

A variety of approaches were discussed, and it was agreed that more research into the underlying anatomical basis for this appearance is needed. Some faculty members recommended building up the philtral columns and resurfacing the skin. Others suggested that a small amount of BoNTA (e.g., 0.5 to 2 U) in the infracolumellar area could be effective, particularly in patients whose nasal tip droops when they smile. Some faculty members reported success with 1 U of BoNTA directly under the nose. The treatment is similar to that for nasal tip elevation but depends on the presentation. Another approach is to inject 0.5 to 1 U into each levator labii just lateral to the nasal ala on each side. Understanding and observing the muscle actions in this area are important in determining the treatment.

Risorius

The risorius muscle moves the lips laterally and is responsible for smiling or grimacing. It sometimes results in an unwanted or unintended negative expression if the muscle is hyperdynamic. One unit of BoNTA may reduce this activity if it is excessive. Electromyography-guided injection may increase the accuracy of delivering toxin to this muscle.

Excessive Gingival Display (Gummy Smile)

The use of BoNTA to treat excessive gingival display is a minimally invasive alternative to surgery.^{81,82} In this approach, small amounts of BoNTA are used to treat the muscles associated with raising the upper lip, thereby reducing their activity and lengthening the lip line. The elevator muscles of the upper lip include the levator labii superioris, levator labii superioris alaeque nasi, levator anguli oris, zygomaticus major and minor, and depressor septi nasi.⁸² In this area, because of the interplay of muscles, conservative treatment is essential. One pilot study recommends 2.5 U per side at the levator labii superioris, 2.5 U per side at the levator labii superioris/zygomaticus minor, and 1.25 U in the orbicularis oris (2 to 3 mm inferior to the nostrils and 2 to 3 mm from the midline).⁸² Other recommendations are up to 5 U per site at the levator labii superioris alaeque nasi just above the periosteum, which can be identified by placing a fingertip on the pyriform aperture below the nasomaxillary groove.⁸¹ Overtreatment can result in lip ptosis, lower lip protrusion, the possibility of asymmetries, and excessive lengthening of the upper lip. The faculty members who

treat gummy smile tend to inject more conservatively, using about 1 to 2 U per side or 2 to 3 U in the depressor septae at the base of the columella.

Masseter Reduction

Techniques for using BoNTA to treat hypertrophic masseter muscles are well reported in the literature, are particularly evident in Korean-language publications (J. Wu, personal communication; C. Maas, personal communication, April of 2007), and are also reported in articles on treating temporomandibular dysfunctions.^{83,84} English-language publications document the efficacy of approximately 25 to 30 U of BoNTA per side for masseter reduction.⁸³⁻⁸⁷ It is important that BoNTA be used to treat facial widening only when the masseter is involved and not when mandibular bony prominence is the underlying cause.¹¹ Faculty members who treat this area generally start with 10 U of BoNTA per side, but increase the dose to at least 20 U per side when needed. It was noted that it may take at least 6 months for optimal results to appear and up to a year for substantial recontouring to become apparent. Retreatments are at 3- to 4-month intervals. To perform the injection, have the patient bite down so that the anterior and posterior borders of the masseter can be felt. Injections should be low, just above the mandible, with one to two sites per side. By starting with 5 U per site, patients can be checked for side effects such as chewing difficulties and nighttime tooth grinding. Doses can be increased to as much as 25 to 50 U as needed and as tolerated.

Earlobe Volume

With age, the earlobes sag and develop creases. Hyaluronic acid fillers can be used to fill the sagging lobe and rejuvenate appearance. Women who have had repairs due to earrings pulling through and tearing the earlobe can benefit from the tissue-expanding effects of hyaluronic acid filler. In the faculty's experience, the effects are very long-lasting, perhaps because that region is not very active metabolically and is not subject to movement.

Emerging Trends

The shift from a two-dimensional focus to a three-dimensional approach to minimally invasive facial rejuvenation has reinforced the idea of creating overall facial harmony and balance, within the confines of cultural, ethnic, and gender-related goals and ideals. With this approach comes an appreciation of the need for substantial vol-

umes of hyaluronic acid filler to achieve optimal outcomes. This often entails substantial patient education, to ensure realistic expectations and to foster a commitment to longer-term maintenance with sufficient product to provide a high degree of satisfaction. In tandem, it is now recognized that relaxing the muscles of the lower face can play an important role in combination with fillers. In addition, BoNTA treatments, begun at earlier ages, can aid in line prevention. For example, facial lines were compared in a set of identical female twins.⁸⁸ One twin had received BoNTA treatments in the upper face regularly for 13 years. The other twin had received only two treatments in the glabella and forehead. The minimally treated twin had visible lines at rest in the forehead and glabella, whereas the regularly treated twin did not. Differences were also apparent in the crow's feet during smiling. No adverse events were associated with regular treatment. This comparison suggests that long-term treatment with BoNTA can be used safely to prevent the development of lines that are visible at rest.

Faculty members concurred that multimodal approaches to facial rejuvenation and enhancement help clinicians to provide the most satisfactory outcomes for their patients. Resurfacing with light/laser treatments or chemical peels, along with line management, volumizing, and recontouring, has proven to be both safe and effective. For example, the use of nonablative lasers, intense pulsed light, or radiofrequency when used immediately after BoNTA treatment does not reduce the efficacy of BoNTA treatment.⁸⁹ Indeed, BoNTA plus laser treatment increases the extent and longevity of improvement compared with laser treatment alone.⁹⁰⁻⁹² In addition, BoNTA plus intense pulsed light improves outcomes over intense pulsed light alone when the crow's feet are treated.⁹³ Similarly, radiofrequency, lasers, or intense pulsed light can be used safely and effectively in combination with hyaluronic acid filler to treat nasolabial folds and perioral rhytides.^{94,95}

Given their experience, the faculty cautioned that edema from other treatments, such as fractional laser therapy,⁹⁶ could distort the anatomy, which could affect filler placement and potential migration of neurotoxin. Therefore, any multimodal treatment plans should take such effects into consideration.

Not to be neglected are topical treatments, such as cosmeceuticals, to protect against photodamage, aid in retexturing of the skin, and serve as an important adjunct to other aesthetic products and procedures.⁹⁷ A variety of products are available, and many patients can benefit from

their clinician's advice on these products to minimize the risk of hypersensitivity reactions while maximizing benefit. Nearly 70 percent of the faculty members routinely discuss antioxidant supplements and topical treatments with their patients. An effective sunblock is considered one of the most important topical agents that patients can use.⁹⁷ In addition to protecting against photoaging, sunblock may also help prevent hyperpigmentation after other aesthetic treatments. Despite general awareness of the need for sun protection, many patients can benefit from education about the types of ultraviolet radiation and how to protect against them most effectively and regularly.

Summary: Other Advanced Techniques and Emerging Trends

In discussing the use of BoNTA and hyaluronic acid fillers, the faculty members noted that both types of products can be used in a broad spectrum of applications. BoNTA, for example, can be used to advantage whenever restricting muscle movement, position, or size is likely to provide aesthetic benefits. These uses include masseter reduction, reduction of excessive gingival display, and prevention of line or scar formation. Hyaluronic acid fillers are advantageous overall for volume restoration and recontouring, including in such new uses as earlobe volume restoration and scar filling. Both BoNTA and hyaluronic acid fillers are integral to multimodal approaches to facial rejuvenation and enhancement that include light and laser techniques as well as topical treatments such as cosmeceuticals. Together, these approaches can help clinicians and patients achieve highly satisfactory outcomes.

GENERAL TECHNIQUES

Anesthesia

Because facial areas differ in their sensitivity to pain, the use of various forms of anesthesia depends on both the product and the area of injection. In the lower face and lips, all faculty members

use intraoral blocks (e.g., lidocaine and articaine, with or without epinephrine). All also use ice and many use a Zimmer cooler. Topical anesthetics with agents such as lidocaine are also a useful adjunct. Massagers for vibration anesthesia are used by approximately 30 percent of the faculty. In the midface, none of the faculty members uses a block to treat the malar areas, whereas approximately 40 percent use blocks for treating the nasolabial folds. In the nasojugal groove, 85 percent use a topical anesthetic, 65 percent use ice, and various members of the faculty occasionally use injectable anesthesia, facial cooling, and massage. Only topical agents are used when the upper face is being treated.

Needles and Syringes

The needles and syringes used by faculty members depend on both individual technique/preference and specific application. Faculty members recommended 31-gauge needles with a short hub (30-U insulin syringe), 29-gauge, half-inch to 1-inch needles (0.30-ml syringe; BD Medical, Franklin Lakes, N.J.), tuberculin syringes with 30- or 32-gauge needles, and the hubless, 30/31-gauge system. All faculty members use half-inch needles in their practices, and approximately 30 percent use 1-inch to 1¼-inch needles for certain applications. Some faculty members use 32-gauge needles with a tuberculin syringe because their sharpness and thinness decrease injection pain.

Avoiding Complications and Posttreatment Recommendations

Injection-site reactions, such as erythema, edema, and ecchymosis, are the most common side effects of treatment. Before treatment, patients should be cautioned to avoid any agents that may inhibit clotting for several days before treatment (Table 10).^{3,24,35} All faculty members recommended sterile techniques and also have patients remove all makeup before treatment. After treatment, the use of ice to minimize swelling and bruising is important, and the majority of faculty

Table 10. General Recommendations to Avoid and Manage Complications

Potential Complications	Management Approach
Hypersensitivity reactions	Rare; avoid in patients sensitive to any ingredient in the formulation
Injection-site reactions (e.g., erythema, edema, ecchymosis)	Patient should avoid nonsteroidal anti-inflammatory drugs, alcohol, and vitamin E for at least several days before treatment; injector should apply firm pressure after treatment; use ice packs
History of cold sores (herpes labialis, oral herpes simplex infection)	1 g of valacyclovir (orally) on the day of treatment; prescription for valacyclovir to be taken if needed

members have their patients use ice while still in the office. Although it was previously recommended that patients contract the muscles treated with BoNTA to facilitate neurotoxin uptake,³ none of the faculty members recommended such an approach after combination treatment. All faculty members massage the treatment area after injections, but fewer than 50 percent have their patients massage the area at home.

None of the faculty members advises patients to avoid sun specifically after BoNTA treatment, although sun protection is always important; 28 percent permit their patients to exercise immediately after treatments; an additional 50 percent allow exercise the same day; and the remaining suggest waiting 1 day. Research is needed on the effects of exercise on both BoNTA and hyaluronic acid filler treatments.

Patient Expectations and Concerns

It is prudent to attempt to uncover the patient's expectations, anxieties, or distress as well as potential misinformation that may derive from the experience of friends or from other sources, such as magazine articles. These discussions also provide an opportunity for the practitioner to identify patients who may not be suitable candidates for treatment and to foster a long-term plan with those who are.

Some practitioners suggested asking patients to bring photographs of themselves dating back 5 to 10 years to help guide the treatment plan and establish realistic goals. One of the most important recommendations is to photograph all areas of the face and not just those undergoing treatment. Having a number of views available can help in the accurate assessment of the face and can be useful to show to patients when they return with questions or issues with their treatment. Photographs can also be used to document outcomes.

Other Practice Management Considerations

All of the faculty noted that their staff members are an integral part of their practices and play an important role in office management, patient comfort and retention, follow-up, and identification of potentially problematic patients. Approximately 65 percent of the faculty employ a business manager to handle many of the office financial matters, including billing, discounts, and payment arrangements, leaving the physician to focus on the practice of medicine.

Patient retention is important, and more than 60 percent of the faculty schedule the next ap-

pointment before the patient leaves the office. The vast majority (87 percent) of the faculty and their staff also correspond with their patients by e-mail. Scheduling follow-up telephone calls is another way to improve retention, but in all of these approaches, it is important to maintain confidentiality. All faculty members take strong steps to ensure patient confidentiality and to prevent staff from divulging any patient information outside the office. Typically, any breach of patient confidentiality is grounds for immediate dismissal.

Patient Satisfaction

Most faculty associate patient retention with patient satisfaction. Only one faculty member surveys patients on a routine basis. If validated instruments such as Facial Line Outcomes and Self-Perception of Age⁹ are available for more areas of the face, they are likely to be used. Development of such instruments may help track and enhance patient satisfaction with various aesthetic procedures and with a physician's practice.

OVERALL SUMMARY AND CONCLUSIONS

The number of minimally invasive aesthetic products and procedures has burgeoned in the last several years. In concert, clinicians have continued to expand and refine their techniques to provide their patients with optimal outcomes and a high level of satisfaction. Together, BoNTA and hyaluronic acid fillers are a mainstay of facial rejuvenation, accounting for approximately 54 percent of all nonsurgical aesthetic procedures performed in the United States. Use of these products is increasing among various demographic populations, including among persons of color and those with diverse ethnic backgrounds.

At the same time, concepts of aging and rejuvenation have changed from a somewhat two-dimensional focus to an appreciation of the three-dimensional aspects of aging, including the contribution of volume loss to appearance. A thorough knowledge of the process of facial aging and the anatomy and physiology of the facial musculature is paramount to treat patients successfully. With this understanding has come a paradigm shift from treating wrinkles and lines to relaxing the musculature, restoring volume, and recontouring to provide a balanced, harmonious aesthetic result. Although the various areas of the face lend themselves to different treatments, the overwhelming trend is toward increased combined use

of BoNTA and hyaluronic acid fillers as well as other modalities, such as resurfacing.

Notably, the combination of BoNTA and hyaluronic acid filler appears to increase the longevity of the outcomes, an issue of importance to patients. More than ever, patient education and counseling are essential when developing a comprehensive treatment plan, so that patients can make informed decisions about their treatment choices. Clinicians must also be knowledgeable about the strengths and limitations of various products and how they may be used optimally to individualize treatment for patient needs and goals.

It has also become apparent that, although it is necessary to discuss regions of the face individually, treating areas of the face in isolation does not yield the best possible outcomes for patients. Key insights and recommendations were provided by the faculty for each major region of the face as well as specific areas within those regions. It was stressed that treatment of any one area may have a considerable effect on other areas that should be evaluated as treatment progresses. In addition, the importance of understanding how to avoid or manage complications was addressed in detail. The faculty members emphasized that certain advanced techniques described in the supplement should not be undertaken by inexperienced injectors.

For the upper face, faculty agreed that BoNTA remains the foundation of treatment but that hyaluronic acid fillers can augment results in several ways, including the management of deep resting folds and lines that remain after BoNTA treatment and for the restoration of volume in the eyebrow area. An emerging use of hyaluronic acid fillers is to address the age-related loss of volume in the temple area. One of the BoNTA-specific changes in recommendations since the previous BoNTA consensus meeting was the agreement that lower doses of BoNTA, particularly in the forehead, may help avert a frozen look.

For the midface, the most apparent effect of aging is the loss of volume. Thus, hyaluronic acid fillers play a central role, with BoNTA treatment serving as an important adjunct depending on the specific treatment plan. A key step in facial rejuvenation of the midface is the restoration of volume in the malar region. By treating this area with hyaluronic acid fillers, clinicians can provide a more youthful, rounded area that will affect how other areas of the face, such as the tear troughs and nasolabial folds, are subsequently treated. Importantly, optimal results depend on using sufficient volume, and patients may need to be educated that undertreatment is likely to lead to an

unsatisfactory outcome. In treating the midface, faculty members suggested taking any of a number of steps to avoid asymmetries. For example, mark both sides of the face, use half a syringe on one side and then move to the other, and have the pretreatment photograph(s) available for comparison during the procedure.

In the lower face, both BoNTA and hyaluronic acid fillers are important because rejuvenation involves control of muscle movement as well as restoration of volume. Detailed treatment planning is essential, to avoid asymmetries and poor outcomes. Knowledge of the musculature and its complex interactions is crucial. Treating the perioral area is central to the aesthetic outcome of the lower face, but treatment should be initiated conservatively, with follow-up visits for additional treatments. The differences between shape and volume are important in treatment planning and in the optimal use of products. Faculty members stressed that it is valuable to ensure that patients appreciate that not all treatments must be performed in a single session.

The faculty members also provided information and recommendations on other advanced techniques in the use of BoNTA and hyaluronic acid fillers and emerging trends in facial rejuvenation. These techniques include, but are not limited to, the use of BoNTA to recontour the mandible area and to reduce excessive gingival display; combination treatment with BoNTA and hyaluronic acid filler to refine the appearance of chin implants and improve acne and other scars; the use of hyaluronic acid filler to augment earlobe volume; and the use of both BoNTA and hyaluronic acid filler in combination with other modalities, such as laser and light treatments. Specific information on general techniques and practices, such as anesthesia, needles and syringes, avoiding complications, and posttreatment recommendations, is also detailed. Patient selection, education, and counseling, as well as other practice management issues, are considered.

In conclusion, the information presented in this supplement represents the insights and recommendations of medical experts in facial aesthetics on the use of BoNTA and hyaluronic acid fillers in facial rejuvenation. This supplement recognizes that facial aesthetics is a rapidly evolving field of medicine in which physicians and patients continue to have a major interest in the benefits of safe and effective, minimally invasive products and procedures that afford high levels of satisfaction to both clinicians and patients.

APPENDIX: THE FACIAL AESTHETICS CONSENSUS GROUP

The following faculty members comprise the Facial Aesthetics Consensus Group:

Richard L. Anderson, M.D.
Plastic Surgery
Salt Lake City, Utah

Joel L. Cohen, M.D.
Dermatology
Englewood, Colo.

Sue Ellen Cox, M.D.
Dermatology
Chapel Hill, N.C.

Steven H. Dayan, M.D.
Facial Plastic Surgery
Chicago, Ill.

Zoe Diana Draelos, M.D.
Dermatology
High Point, N.C.

Steven Fagien, M.D.
Ophthalmic Plastic Surgery
Boca Raton, Fla.

Ellen C. Gendler, M.D.
Dermatology
New York, N.Y.

Mitchel P. Goldman, M.D.
Dermatology
La Jolla, Calif.

Mary P. Lupo, M.D.
Dermatology
New Orleans, La.

Corey S. Maas, M.D.
Otolaryngology
San Francisco, Calif.

Susan C. Taylor, M.D.
Dermatology
New York, N.Y.

Jessica Wu, M.D.
Dermatology
Los Angeles, Calif.

Steven G. Yoelin, M.D.
Ophthalmology
Newport Beach, Calif.

APPENDIX: FACULTY DISCLOSURES

The Postgraduate Institute for Medicine assesses conflict of interest with its instructors, planners, managers, and other individuals who are in

a position to control the content of continuing medical education activities. All relevant conflicts of interest that are identified are thoroughly vetted by the Institute for fair balance, scientific objectivity of studies utilized in this activity, and patient care recommendations. The Postgraduate Institute for Medicine is committed to providing its learners with high-quality continuing medical education activities and related materials that promote improvements or quality in health care and not a specific proprietary business interest of a commercial interest.

The faculty reported the following financial relationships or relationships to products or devices they or their spouse/life partner have with commercial interests related to the content of this CME activity:

Richard L. Anderson, M.D., states that he received consulting fees from Allergan, Inc., and BioForm Medical, Inc., and has received research study support from Allergan, Inc., Ipsen Limited, and Merz Pharmaceuticals. He is a consultant with Medicis Pharmaceutical Corporation.

Andrew Blitzer, M.D., D.D.S., states that he receives royalties from Medtronic Xomed, Inc.; consulting fees from Allergan, Inc., and Solstice Neurosciences, Inc.; contracted research funds from Merz Pharmaceuticals; and an unrestricted research grant from Allergan, Inc.

Jean D. A. Carruthers, M.D., states that she and her spouse receive consulting fees from Allergan, Inc., Artes Medical Inc., BioForm Medical, Inc., Lumenis Ltd., Medicis Pharmaceutical Corporation, Merz Pharmaceuticals, Ortho Neutrogena, Solstice Neurosciences, Inc., and Unilever, Canada; and contracted research funds from Allergan, Inc., BioForm Medical Inc., Medicis Pharmaceutical Corporation, Merz Pharmaceuticals, Ortho Neutrogena, Q-Med, Inc., and Richard James Inc.; and have ownership interest in Artes Medical, Inc., and BioForm Medical, Inc.

Joel L. Cohen, M.D., states that he receives consulting fees from Allergan, Inc., BioForm Medical, Inc., Medicis Pharmaceutical Corporation; fees for non-Continuing Medical Education services received directly from a commercial interest or their agents from Allergan, Inc.; and contracted research funds from Allergan, Inc., BioForm Medical, Inc., and Medicis Pharmaceutical Corporation.

Sue Ellen Cox, M.D., states that she and her spouse receive consulting fees and contracted research funds from Allergan, Inc.

Steven H. Dayan, M.D., states that he receives consulting fees from BioForm Medical, Inc., and Medicis Pharmaceutical Corporation; fees for

non-Continuing Medical Education services received directly from a commercial interest or their agents from Aesthera Corp. and Laserscope; and contracted research funds from Aesthera Corp., Allergan, Inc., BioForm Medical, Inc., Contura International A/S, and Medicis Pharmaceutical Corporation.

Zoe Diana Draelos, M.D., states that she has been a consultant or researcher for Abgenix, Inc., Allergan, Inc., Altan, Inc., Amgen Inc., Andrew Jergens Co., Avon Products, Inc., Bayer AG, Clay-Parks Laboratories, Inc., Colgate-Palmolive Co., Coloplast Group, Combe Incorporated, Coria Laboratories, Ferndale Laboratories, Inc., Fujisawa Healthcare, Inc., Galderma International, Genentech, Inc., General Mills, Inc., GlaxoSmith-Kline plc, Greystone Medical Group, Inc., Intendis GmbH, Healthpoint Ltd., Hydron Technologies, Inc., L'Oreal SA, Medicis Pharmaceutical Corporation, Merck & Co., Inc., Milliken & Company, NeoStrata Company, Niadyne, Inc., Novartis AG, Nu Skin Enterprises, Pacific Biosciences Laboratories, Inc., Paddock Laboratories, Inc., Pfizer Inc., Pharma Cosmetix Research LLC, Procter & Gamble, Schick Wilkinson-Sword, Teva Pharmaceuticals Industries Ltd., Taro Pharmaceutical Industries Ltd., TherOx, Inc., Wrigley Corporation, and Wyeth Pharmaceuticals, Inc.

Steven Fagien, M.D., states that neither he nor his spouse has any financial relationships or relationships to products or devices with any commercial interests related to the content of this Continuing Medical Education activity.

Ellen C. Gendler, M.D., states that she receives consulting fees from Allergan, Inc., and Medicis Pharmaceutical Corporation.

Richard G. Glogau, M.D., states that he receives consulting fees from Allergan, Inc., FibroGen, Inc., Gerson Lehrman Group, Inc., LipoSonix, Inc., MEDACorp, Neutrogena Corporation, and Revance Therapeutics, Inc.; fees for non-Continuing Medical Education services received directly from a commercial interest or their agents from Medicis Pharmaceutical Corporation; and contracted research funds from Allergan, Inc., Colbar Life Science Ltd., Contura International A/S, FibroGen, Inc., FzioMed, Inc., LipoSonix, Inc., Medicis Pharmaceutical Corporation, and Revance Therapeutics, Inc.

Mitchel P. Goldman, M.D., states that he receives consulting fees from Allergan, Inc., Lumenis Ltd., Medicis Pharmaceutical Corporation, and Mentor Corporation; fees for non-Continuing Medical Education services received directly from a commercial interest or their agents from Allergan, Inc., Lumenis Ltd., Medicis Pharmaceutical Corporation, and Mentor Corporation; and contracted research funds from Allergan, Inc., Lume-

nis Ltd., Medicis Pharmaceutical Corporation, and Mentor Corporation; and contracted research funds from Allergan, Inc., Lumenis Ltd., Medicis Pharmaceutical Corporation, and Mentor Corporation; and has ownership interest in Lumenis Ltd. and CoolTouch, Inc.

Mary P. Lupo, M.D., states that she receives consulting fees from Dermik Aesthetics and fees for non-Continuing Medical Education services received directly from a commercial interest or their agents from Allergan, Inc.

Corey S. Maas, M.D., states that he receives research/consulting fees, advisory board honoraria, and/or stock interest from Allergan, Inc., BioForm Medical, Inc., Colbar Life Science Ltd., Elan Pharmaceuticals, Inc., and Mentor Corporation; and speaker fees from Medicis Pharmaceutical Corporation.

Susan C. Taylor, M.D., states that she receives consulting fees from Barrier Therapeutics, Inc., Beiersdorf AG, Dermik Aesthetics, Galderma Laboratories, L.P., Johnson & Johnson, Medicis Pharmaceutical Corporation, Procter & Gamble, Stiefel Laboratories, Inc.; fees for non-Continuing Medical Education services received directly from a commercial interest or their agents from Allergan, Inc., Barrier Therapeutics, Inc., Dermik Aesthetics, Doak Dermatologics, Galderma Laboratories, L.P., Johnson & Johnson, Medicis Pharmaceutical Corporation, Novartis Pharmaceuticals Corporation; and contracted research funds from Amgen, Inc., Atrix, Atrix/Fujisawa, Barrier Therapeutics, Inc., Beiersdorf AG, Doak Dermatologics, Galderma Laboratories, L.P., Genzyme Corporation, Johnson & Johnson, LEO Pharma A/S, Medicis Pharmaceutical Corporation, Palomar Medical Technologies, Stiefel Laboratories, Inc., and Teva Pharmaceutical Industries Ltd.

Jessica Wu, M.D., states that she receives consulting fees from Allergan, Inc., Dermik Aesthetics, Johnson & Johnson, and Stiefel Laboratories, Inc., and contracted research funds from Allergan, Inc.

Steven G. Yoelin, M.D., states that he receives consulting fees from Allergan, Inc., BioForm Medical, Inc., Sanofi-Aventis, and Valeant, Inc.; fees for non-Continuing Medical Education services from Allergan, Inc. and Medicis Pharmaceutical Corporation; and contracted research funds from Allergan, Inc.

The planners and managers reported the following financial relationships or relationships to products or devices they or their spouse/life partner have with commercial interests related to the content of this CME activity:

The PIM clinical content reviewer, **Trace Hutchinson, Pharm.D.**, hereby states that neither he nor his spouse has any financial relationships or relationships to products or devices with any commercial interests related to the content of this Continuing Medical Education activity.

The HLS reviewers, **Paula G. Davis, Ph.D.**, and **Ramana Yalamanchili, Ph.D.**, state that neither they nor their spouses/life partners have any financial relationships or relationships to products or devices with any commercial interests related to the content of this Continuing Medical Education activity.

Jean D. A. Carruthers, M.D.

University of British Columbia
Suite 740-943 West Broadway
Vancouver, V5Z 4E1 British Columbia, Canada
drjean@carruthers.net

ACKNOWLEDGMENT

This activity is supported by an educational grant provided by Allergan, Inc.

REFERENCES

- de Maio, M. The minimal approach: An innovation in facial cosmetic procedures. *Aesthetic Plast. Surg.* 28: 295, 2004.
- Bosniak, S., Cantisano-Zilkha, M., Purewal, B. K., et al. Combination therapies in oculofacial rejuvenation. *Orbit* 25: 319, 2006.
- Carruthers, J., Fagien, S., Matarasso, S. L., et al. Consensus recommendations on the use of botulinum toxin type A in facial aesthetics. *Plast. Reconstr. Surg.* 114 (Suppl. 6): 1S, 2004.
- American Society for Aesthetic Plastic Surgery. Cosmetic surgery national data bank: 2006 statistics. Available at: <http://www.surgery.org/download/2006stats.pdf>. Accessed December 12, 2007.
- American Society for Aesthetic Plastic Surgery. ASAPS 2000 statistics on cosmetic surgery. Available at: <http://www.surgery.org/download/2000stats.pdf>. Accessed November 27, 2007.
- Donath, A. S., Glasgold, R. A., and Glasgold, M. J. Volume loss versus gravity: New concepts in facial aging. *Curr. Opin. Otolaryngol. Head Neck Surg.* 15: 238, 2007.
- Fagien, S. Botulinum toxin type A for facial aesthetic enhancement: Role in facial shaping. *Plast. Reconstr. Surg.* 112 (Suppl.): 6S, 2003.
- Coleman, K. R., and Carruthers, J. Combination therapy with BOTOX and fillers: The new rejuvenation paradigm. *Dermatol. Ther.* 19: 177, 2006.
- Carruthers, J., and Carruthers, A. Botulinum toxin type A treatment of multiple upper facial sites: Patient-reported outcomes. *Dermatol. Surg.* 33: S10, 2007.
- Flynn, T. C. Update on botulinum toxin. *Semin. Cutan. Med. Surg.* 25: 115, 2006.
- Dayan, S. H., and Maas, C. S. Botulinum toxins for facial wrinkles: Beyond glabellar lines. *Facial Plast. Surg. Clin. North Am.* 15: 41, 2007.
- Aoki, K. R., and Guyer, B. Botulinum toxin type A and other botulinum toxin serotypes: A comparative review of biochemical and pharmacological actions. *Eur. J. Neurol.* 8 (Suppl. 5): 21, 2001.
- Aoki, K. R. A comparison of the safety margins of botulinum neurotoxin serotypes A, B, and F in mice. *Toxicon* 39: 1815, 2001.
- Allergan, Inc. Botox Cosmetic [package insert]. Irvine, Calif.: Allergan, Inc., 2005.
- Ipsen Limited. Dysport [package insert]. Berkshire, U.K.: Ipsen Limited, 2007.
- Trindade de Almeida, A. R., Marques, E., de Almeida, J., Cunha, T., and Boraso, R. Pilot study comparing the diffusion of two formulations of botulinum toxin type A in patients with forehead hyperhidrosis. *Dermatol. Surg.* 33: S37, 2007.
- Lowe, N. J., Yamauchi, P. S., Lask, G. P., et al. Botulinum toxins types A and B for brow furrows: Preliminary experiences with type B toxin dosing. *J. Cosmet. Laser. Ther.* 4: 15, 2002.
- Solstice Neurosciences, Inc. Myobloc [package insert]. South San Francisco, Calif.: Solstice Neurosciences, Inc., 2004.
- Wenzel, R., Jones, D., and Borrego, J. A. Comparing two botulinum toxin type A formulations using manufacturers' product summaries. *J. Clin. Pharm. Ther.* 32: 387, 2007.
- Aoki, K. R., Satorius, A., Ardila, C., et al. Pharmacology of Botox, Dysport, Myobloc and BTX-A in animal models of efficacy and safety. Abstract presented at the International Conference on Basic and Therapeutic Aspects of Botulinum and Tetanus Toxins, Denver, Colo., June 23–25, 2005.
- Lowe, P. L., Patnaik, R., and Lowe, N. J. A comparison of two botulinum type A toxin preparations for the treatment of glabellar lines: Double-blind, randomized, pilot study. *Dermatol. Surg.* 31: 1651, 2005.
- Hirsch, R. J., and Cohen, J. L. Soft tissue augmentation. *Cutis* 78: 165, 2006.
- Monheit, G. D., and Coleman, K. M. Hyaluronic acid fillers. *Dermatol. Ther.* 19: 141, 2006.
- Born, T. Hyaluronic acids. *Clin. Plast. Surg.* 33: 525, 2006.
- Goa, K. L., and Benfield, P. Hyaluronic acid: A review of its pharmacology and use as a surgical aid in ophthalmology, and its therapeutic potential in joint disease and wound healing. *Drugs* 47: 536, 1994.
- Tezel, A., and Walker, P. S. The science of extrusion force in hyaluronic acid dermal fillers. Poster presented at the American Academy of Dermatology 65th Annual Meeting, Washington, D.C., February 2–6, 2007.
- Hotta, T. Dermal fillers: The next generation. *Plast. Surg. Nurs.* 24: 14, 2004.
- Medicis Aesthetics, Inc. Restylane [package insert]. Scottsdale, Ariz.: Medicis Aesthetics, Inc., 2005.
- Medicis Aesthetics, Inc. Perlane [package insert]. Scottsdale, Ariz.: Medicis Aesthetics, Inc., 2006.
- Inamed Aesthetics. Juvéderm Ultra [package insert]. Santa Barbara, Calif.: Inamed Aesthetics, 2007.
- Inamed Aesthetics. Juvéderm Ultra Plus [package insert]. Santa Barbara, Calif.: Inamed Aesthetics, 2007.
- Tezel, A., and Walker, P. S. The influence of formulation on persistence with hyaluronic acid dermal fillers. Poster presented at the American Academy of Dermatology 65th Annual Meeting, Washington, D.C., February 2–6, 2007.
- Allergan Inc. announces FDA approval of label extensions for Juvéderm Ultra and Juvéderm Ultra Plus [press release]. Available at: http://www.biospace.com/news_story.aspx?NewsEntityId=61178. Accessed June 27, 2007.
- Narins, R. S., and Bowman, P. H. Injectable skin fillers. *Clin. Plast. Surg.* 32: 151, 2005.
- de Bouille, K. Management of complications after implantation of fillers. *J. Cosmet. Dermatol.* 3: 2, 2004.

36. Klein, A. W. The art and science of injectable hyaluronic acids (Discussion). *Plast. Reconstr. Surg.* 117: 35S, 2006.
37. Cohen, S. R., Berner, C. F., Busso, M., et al. ArteFill: A long-lasting injectable wrinkle filler material—Summary of the U.S. Food and Drug Administration trials and a progress report on 4- to 5-year outcomes. *Plast. Reconstr. Surg.* 118: 64S, 2006.
38. Lupo, M. P. Hyaluronic acid fillers in facial rejuvenation. *Semin. Cutan. Med. Surg.* 25: 122, 2006.
39. Rohrich, R. J., and Pessa, J. E. The fat compartments of the face: Anatomy and clinical implications for cosmetic surgery. *Plast. Reconstr. Surg.* 119: 2219, 2007.
40. Mendelson, B. C., Hartley, W., Scott, M., et al. Age-related changes of the orbit and midcheek and the implications for facial rejuvenation. *Aesthetic Plast. Surg.* 31: 419, 2007.
41. Tan, S. R., and Glogau, R. G. Filler esthetics. In A. Carruthers and J. Carruthers (Eds.), *Procedures in Cosmetic Dermatology Series: Soft Tissue Augmentation*. Philadelphia, Pa.: Saunders, 2005.
42. Tan, S. R., and Glogau, R. G. Botox esthetics. In A. Carruthers and J. Carruthers (Eds.), *Procedures in Cosmetic Dermatology Series: Botulinum Toxin*. Philadelphia, Pa.: Saunders, 2005.
43. Draelos, Z. D. Concepts in a multiprong approach to photoaging. *Skin Ther. Lett.* 11: 1, 2006.
44. Rexbye, H., Petersen, I., Johansens, M., et al. Influence of environmental factors on facial ageing. *Age Ageing* 35: 110, 2006.
45. Benedetto, A. V., and Lahti, J. G. Measurement of the anatomic position of the corrugator supercilii. *Dermatol. Surg.* 31: 923, 2005.
46. Ferrario, V. F., Sforza, C., Serrao, G., et al. Growth and aging of facial soft tissues: A computerized three-dimensional mesh diagram analysis. *Clin. Anat.* 16: 420, 2003.
47. Draelos, Z. D. The shrinking world: Skin considerations in a global community. *J. Cosmet. Dermatol.* 5: 1, 2006.
48. Porter, J. P., and Lee, J. I. Facial analysis: Maintaining ethnic balance. *Facial Plast. Surg. Clin. North Am.* 10: 343, 2002.
49. Kelly, A. P. Aesthetic considerations in patients of color. *Dermatol. Clin.* 15: 687, 1997.
50. Ahn, K. Y., Park, M. Y., Park, D. H., et al. Botulinum toxin A for the treatment of facial hyperkinetic wrinkle lines in Koreans. *Plast. Reconstr. Surg.* 105: 778, 2000.
51. Sykes, J. M. Management of the aging face in the Asian patient. *Facial Plast. Surg. Clin. North Am.* 15: 353, 2007.
52. Lam, S. M. Aesthetic strategies for the aging Asian face. *Facial Plast. Surg. Clin. North Am.* 15: 283, 2007.
53. Boyd, C. M. Approaches to the aging face in African American patients. *Facial Plast. Surg. Clin. North Am.* 10: 377, 2002.
54. Jackson, B. A. Cosmetic considerations and nonlaser cosmetic procedures in ethnic skin. *Dermatol. Clin.* 21: 703, 2003.
55. Grimes, P. E. A four-month randomized, double-masked evaluation of the efficacy of botulinum toxin type A for the treatment of glabellar lines in women with skin types V and VI. Poster presented at the American Academy of Dermatology 62nd Annual Meeting, Washington, D.C., February 6–11, 2004.
56. Grimes, P. E., Thomas, J. A., Murphy, D. K., et al. Efficacy and safety of novel hyaluronic acid-based fillers and crosslinked bovine collagen in Caucasians and persons of color. Poster presented at the American Academy of Dermatology's Academy '06 Meeting, San Diego, Calif., July 26–30, 2006.
57. Flynn, T. C., Carruthers, J. A., and Carruthers, J. A. Botulinum-A toxin treatment of the lower eyelid improves infraorbital rhytides and widens the eye. *Dermatol. Surg.* 27: 703, 2001.
58. Balikian, R. V., and Zimble, M. S. Primary and adjunctive uses of botulinum toxin type A in the periorbital region. *Otolaryngol. Clin. North Am.* 40: 291, 2007.
59. Carruthers, A., and Carruthers, J. Eyebrow height after botulinum toxin type A to the glabella. *Dermatol. Surg.* 33: S26, 2007.
60. Huilgol, S. C., Carruthers, A., and Carruthers, J. D. Raising eyebrows with botulinum toxin. *Dermatol. Surg.* 25: 373, 1999.
61. Ahn, M. S., Catten, M., and Maas, C. S. Temporal brow lift using botulinum toxin A. *Plast. Reconstr. Surg.* 105: 1129, 2000.
62. Cohen, J. L., and Dayan, S. H. Botulinum toxin type A in the treatment of dermatochalasis: A prospective study evaluating temporal brow elevation. Poster presented at the American Academy of Dermatology's 63rd Annual Meeting, New Orleans, La., February 18–22, 2005.
63. Kornstein, A. N. Soft-tissue reconstruction of the brow with Restylane. *Plast. Reconstr. Surg.* 116: 2017, 2005.
64. Maas, C. S. Botulinum neurotoxins and injectable fillers: Minimally invasive management of the aging upper face. *Facial Plast. Surg. Clin. North Am.* 14: 241, 2006.
65. Carruthers, J., and Carruthers, A. A prospective, randomized, parallel group study analyzing the effect of BTX-A (Botox) and nonanimal sourced hyaluronic acid (NASHA, Restylane) in combination compared with NASHA (Restylane) alone in severe glabellar rhytides in adult female subjects: Treatment of severe glabellar rhytides with a hyaluronic acid derivative compared with the derivative and BTX-A. *Dermatol. Surg.* 29: 802, 2003.
66. Carruthers, J., and Carruthers, A. The use of botulinum toxin type A in the upper face. *Facial Plast. Surg. Clin. North Am.* 14: 253, 2006.
67. Carruthers, J., and Carruthers, A. Complications of botulinum toxin type A. *Facial Plast. Surg. Clin. North Am.* 15: 51, 2007.
68. Bihari, K. Safety, effectiveness, and duration of effect of Botox after switching from Dysport for blepharospasm, cervical dystonia, and hemifacial spasm. *Curr. Med. Res. Opin.* 21: 433, 2005.
69. Nussgens, Z., and Roggenkamper, P. Comparison of two botulinum-toxin preparations in the treatment of essential blepharospasm. *Graefes Arch. Clin. Exp. Ophthalmol.* 235: 197, 1997.
70. Schanz, S., Schippert, W., Ulmer, A., et al. Arterial embolization caused by injection of hyaluronic acid (Restylane). *Br. J. Dermatol.* 146: 928, 2002.
71. Carruthers, J. D., and Carruthers, A. Facial sculpting and tissue augmentation. *Dermatol. Surg.* 31: 1604, 2005.
72. Airan, L. E., and Born, T. M. Nonsurgical lower eyelid lift. *Plast. Reconstr. Surg.* 116: 1785, 2005.
73. Kane, M. A. Treatment of tear trough deformity and lower lid bowing with injectable hyaluronic acid. *Aesthetic Plast. Surg.* 29: 363, 2005.
74. Goldberg, R. A., and Fiaschetti, D. Filling the periorbital hollows with hyaluronic acid gel: Initial experience with 244 injections. *Ophthalm. Plast. Reconstr. Surg.* 22: 335, 2006.
75. Narins, R. S., Brandt, F., Leyden, J., et al. A randomized, double-blind, multicenter comparison of the efficacy and tolerability of Restylane versus Zypplast for the correction of nasolabial folds. *Dermatol. Surg.* 29: 588, 2003.
76. Baumann, L. S., Shamban, A. T., Lupo, M. P., et al. Comparison of hyaluronic acid-based fillers and crosslinked bovine collagen: a double-masked, multicenter, randomized, within-subject study. Poster presented at the American Academy of Dermatology's Academy '06 Meeting, San Diego, Calif., July 26–30, 2006.
77. Dayan, S. H., and Kempiners, J. J. Treatment of the lower third of the nose and dynamic nasal tip ptosis with Botox. *Plast. Reconstr. Surg.* 115: 1784, 2005.

78. Petrus, G. M., Lewis, D., and Maas, C. S. Anatomic considerations for treatment with botulinum toxin. *Facial Plast. Surg. Clin. North Am.* 15: 1, v, 2007.
79. Wynn, R., Bentsianov, B. L., and Blitzer, A. Botulinum toxin injection for the lower face and neck. *Oper. Tech. Otolaryngol. Head Neck Surg.* 15: 139, 2004.
80. Valeant Pharmaceuticals International. Mestinon [package insert]. Costa Mesa, Calif.: Valeant Pharmaceuticals International, 2005.
81. Sengelmann, R. D., Tull, S., and Flynn, T. C. Botulinum toxin in the lips, mid and lower face. In A. Carruthers and J. Carruthers (Eds.), *Procedures in Cosmetic Dermatology Series: Botulinum Toxin*. Philadelphia, Pa.: Saunders, 2005.
82. Polo, M. Botulinum toxin type A in the treatment of excessive gingival display. *Am. J. Orthod. Dentofacial Orthop.* 127: 214, 2005.
83. Song, P. C., Schwartz, J., and Blitzer, A. The emerging role of botulinum toxin in the treatment of temporomandibular disorders. *Oral Dis.* 13: 253, 2007.
84. Bentsianov, B., Francis, A., and Blitzer, A. Botulinum toxin treatment of temporomandibular disorders, masseteric hypertrophy, and cosmetic masseter reduction. *Oper. Tech. Otolaryngol. Head Neck Surg.* 15: 110, 2004.
85. Ahn, J., Horn, C., and Blitzer, A. Botulinum toxin for masseter reduction in Asian patients. *Arch. Facial Plast. Surg.* 6: 188, 2004.
86. Kim, H. J., Yum, K. W., Lee, S. S., et al. Effects of botulinum toxin type A on bilateral masseteric hypertrophy evaluated with computed tomographic measurement. *Dermatol. Surg.* 29: 484, 2003.
87. Park, M. Y., Ahn, K. Y., and Jung, D. S. Botulinum toxin type A treatment for contouring of the lower face. *Dermatol. Surg.* 29: 477, 2003.
88. Binder, W. J. Long-term effects of botulinum toxin type A (Botox) on facial lines: A comparison in identical twins. *Arch. Facial Plast. Surg.* 8: 426, 2006.
89. Semchyshyn, N. L., and Kilmer, S. L. Does laser inactivate botulinum toxin? *Dermatol. Surg.* 31: 399, 2005.
90. West, T. B., and Alster, T. S. Effect of botulinum toxin type A on movement-associated rhytides following CO₂ laser resurfacing. *Dermatol. Surg.* 25: 259, 1999.
91. Zimble, M. S., Holds, J. B., Kokoska, M. S., et al. Effect of botulinum toxin pretreatment on laser resurfacing results: A prospective, randomized, blinded trial. *Arch Facial Plast. Surg.* 3: 165, 2001.
92. Yamauchi, P. S., Lask, G., and Lowe, N. J. Botulinum toxin type A gives adjunctive benefit to periorbital laser resurfacing. *J. Cosmet. Laser Ther.* 6: 145, 2004.
93. Carruthers, J., and Carruthers, A. The effect of full-face broadband light treatments alone and in combination with bilateral crow's feet botulinum toxin type A chemodenervation. *Dermatol. Surg.* 30: 355, 2004.
94. Goldman, M. P., Alster, T. S., and Weiss, R. A randomized trial to determine the influence of laser therapy, monopolar radiofrequency treatment, and intense pulsed light therapy administered immediately after hyaluronic acid gel implantation. *Dermatol. Surg.* 33: 535, 2007.
95. Alam, M., Levy, R., Pavjani, U., et al. Safety of radiofrequency treatment over human skin previously injected with medium-term injectable soft-tissue augmentation materials: A controlled pilot trial. *Lasers Surg. Med.* 38: 205, 2006.
96. Geronemus, R. G. Fractional photothermolysis: Current and future applications. *Lasers Surg. Med.* 38: 169, 2006.
97. Glaser, D. A. Anti-aging products and cosmeceuticals. *Facial Plast. Surg. Clin. North Am.* 12: 363, 2004.

Aesthetic Surgery Journal

<http://aes.sagepub.com/>

Appropriate Selection and Application of Nonsurgical Facial Rejuvenation Agents and Procedures : Panel Consensus Recommendations

Rebecca Fitzgerald, Miles H. Graivier, Michael Kane, Z. Paul Lorenc, Danny Vleggaar, Wm. Philip Werschler and Jeffrey M. Kenkel

Aesthetic Surgery Journal 2010 30: 36S

DOI: 10.1177/1090820X10378697

The online version of this article can be found at:

http://aes.sagepub.com/content/30/1_suppl/36S

Published by:



<http://www.sagepublications.com>

On behalf of:



[American Society for Aesthetic Plastic Surgery](#)

Additional services and information for *Aesthetic Surgery Journal* can be found at:

Email Alerts: <http://aes.sagepub.com/cgi/alerts>

Subscriptions: <http://aes.sagepub.com/subscriptions>

Reprints: <http://www.sagepub.com/journalsReprints.nav>

Permissions: <http://www.sagepub.com/journalsPermissions.nav>

Appropriate Selection and Application of Nonsurgical Facial Rejuvenation Agents and Procedures: Panel Consensus Recommendations

Aesthetic Surgery Journal
30(Suppl 1) 36S-45S
© 2010 The American Society for
Aesthetic Plastic Surgery, Inc.
Reprints and permission:
[http://www.sagepub.com/
journalsPermissions.nav](http://www.sagepub.com/journalsPermissions.nav)
DOI: 10.1177/1090820X10378697
www.aestheticsurgeryjournal.com


Rebecca Fitzgerald, MD; Miles H. Graivier, MD; Michael Kane, MD;
Z. Paul Lorenc, MD, FACS; Danny Vleggaar, MD;
Wm. Philip Werschler, MD; and Jeffrey M. Kenkel, MD

Abstract

As injectable products have been introduced and as clinicians have gained experience with them, applications and techniques for injection have evolved, with better cosmetic results, enhanced patient safety, and greatly improved patient satisfaction. Within the past four years, several consensus recommendation panels have been convened to summarize the accumulated clinical experience and knowledge about the application of these products. The guidelines that already exist in the literature are referred to, and suggested guidelines for the administration of poly-L-lactic acid—for which no consensus guidelines have previously been published—are included in this article.

Keywords

facial rejuvenation, cosmetic medicine, surgical, nonsurgical, fillers, injectables, minimally-invasive

Initially, injectable facial shaping agents other than autologous fat were applied with a focus on filling lines, wrinkles, and folds. This is, of course, how bovine collagen had been employed for more than two decades. However, since the introduction of a number of new agents over the past several years, the focus of treatment has evolved.

Some of these new agents, such as hyaluronic acids (HA), achieve their filling effects—similar to preformed collagen—by simply occupying space. Other agents, such as poly-L-lactic acid (PLLA), actively employ the host reaction and subsequent host fibroplasia to achieve the end result. Still others, such as the currently commercially available forms of polymethylmethacrylate (PMMA) and calcium hydroxylapatite (CaHA), do both. These devices are referred to as “biostimulatory agents” and all fit the currently accepted Williams definition of biocompatibility—that is, “the ability of a biomaterial to elicit an appropriate host response in a specific application.”^{1,2}

The most appropriate (“highest and best”) application of the specific injectable shaping agents is continuously being refined as clinicians gain and share their knowledge of and insights into the pathophysiology of the changes observed in the aging face, as well as their

clinical experience with newer agents designed to address these changes.

GENERAL PRINCIPLES OF AGENT SELECTION

Several simple but important principles should be kept in mind regarding the safe and effective application of the currently available agents.

Dr. Fitzgerald is a Dermatologist in private practice in Los Angeles, California. Dr. Graivier is a Plastic Surgeon in private practice in Atlanta, Georgia. Dr. Michael Kane is an Attending Plastic Surgeon in private practice in New York, New York. Dr. Lorenc is a Plastic Surgeon in private practice in New York, New York. Dr. Vleggaar is Head of Cosmetic Dermatology in private practice in Geneva, Switzerland. Dr. Werschler is Assistant Professor of Dermatology at the University of Washington, Seattle, Washington. Dr. Kenkel is Professor and Vice Chair of Plastic Surgery, University of Texas Southwestern Medical Center.

Corresponding Author:

Jeffrey M. Kenkel, MD, 1801 Inwood Drive, Dallas, TX 75390-9132, USA. E-mail: jeffrey.kenkel@utsouthwestern.edu

Patient Expectations Should Be Aligned With Achievable Results

HA is likely the best choice for a patient seeking an immediate, short-term result (for example, improved appearance for an upcoming social event), whereas PLLA may be the best choice for patient who desires a result with a long duration of effect and understands that the full effect will not be seen immediately.

Patient Selection Rather Than Product Selection May Be the Most Important Factor in Predicting Outcomes

The faces of some patients have a profound and obvious loss in one structural tissue only (a “one-tissue issue”), whereas others may show only slight loss in all structural layers. Consider the patients shown in Figure 1. The patient in Figure 1A will not show improvement without volume; the patient in Figure 1B will not show improvement without a surgical lift. The patient in Figure 1C has more parity of loss in all structural tissue layers, so improvement would be seen with volumization, a surgical lift, or a combination of both.

In general, very conservative amounts of product are needed to correct earlier mild to moderate changes, especially in those with an elastic outer skin envelope capable of accommodating any underlying volume loss. In such patients, facial reshaping and recontouring is cost-effective and likely to be satisfying. In contrast, application of a filler to revolumize a very “empty” face—moderate to severe lipoatrophy, with or without bony remodeling, especially in combination with advanced cutaneous elastosis—would require a great deal of time and product, regardless of the choice of agent.

The Face Should Be Approached as a Whole Three-Dimensional Entity

The patient in Figure 2 underwent treatment of her mid-face alone. Subsequent treatment of the upper and lower third of her face (in this case, using 10 mL of HA) restored perspective and provided a more natural result.

Our New Understanding of the Anatomy of Facial Aging Should Be Utilized to Improve Results

The anatomical studies reviewed in the article titled “Update on Facial Aging”³ provide new insight into where best to “place the replacement” to attain natural-looking corrections, so the data presented there should be reviewed carefully. In short, we now know that the face does not age as one homogeneous object, but as many dynamic components that are best evaluated, modified, and augmented individually.

REGIONS OF THE FACE: OBSERVATIONS FOR CONSIDERATION

Upper Face

Intramuscular injection of a botulinum toxin type A (BTTA) product can be performed to give a more open appearance to the eyes, as well as to raise and alter the shape and position of the brow. It is injected into the procerus and corrugator muscles to correct forehead and glabellar folds and into the lateral orbicularis oculi to treat crow’s feet. For glabellar folds and transverse wrinkles of the forehead, BTTA is the preferred agent. In addition, HA may be considered to further smooth the transitions to the adjacent areas.

Hollowness in the temporal area is best treated by volumizing with injectable shaping agents. Injection of either PLLA or CaHA in the plane below the transtemporalis muscle often provides sufficient lift for treating hollows in the temples. When injecting this area—particularly in older patients—the best results can be obtained by feathering slightly over the zygomatic arch and past the temporal fusion line, thereby blunting the temporal crest. If additional lift is needed in this region, subdermal injection of a biostimulatory filler should be considered, with placement just above the fascia of the temporalis muscle.

Correction of volume loss in the underlying malar region often significantly improves the tear trough and lower lid areas. For smoothing lines that persist in the tear trough and lower lid areas after the underlying malar region has been treated, injections of HA into the medial or lateral sub orbicularis oculi fat can be considered. The injection of any products in this region must be done cautiously and conservatively for two reasons: one is the location of the lacrimal ducts and lower perioral vasculature, and the other is that subcutaneous tissue in this area typically is scant. Therefore, injection of HA to volumize the tear troughs should be done only in patients who have at least a small amount of subcutaneous tissue to avoid the so-called Tyndall effect (a slight bluish hue under the skin). Furthermore, the recommended placement is below, not directly into, the tear trough; the injected product should then be massaged upward.

In the brow area, three elements must be addressed: smoothing, position, and shape. Too often, brow-lift surgery results in changes that are less than aesthetically pleasing. Matros and colleagues⁴ conducted a study to establish an objective goal for such surgery. The authors determined that, unlike most facial areas that descend with aging, the medial brow elevates instead. They conclude that rather than raising the midbrow and medial brow, procedures should focus on elevating the lateral third of the brow. Lambros⁵ has described in detail the use of HA to add volume in the periorbital area.

When brows are sitting too low (“heavy brows”), some lift can be achieved with neurotoxins and filling⁶; however, some patients also may need surgical repositioning. Mild

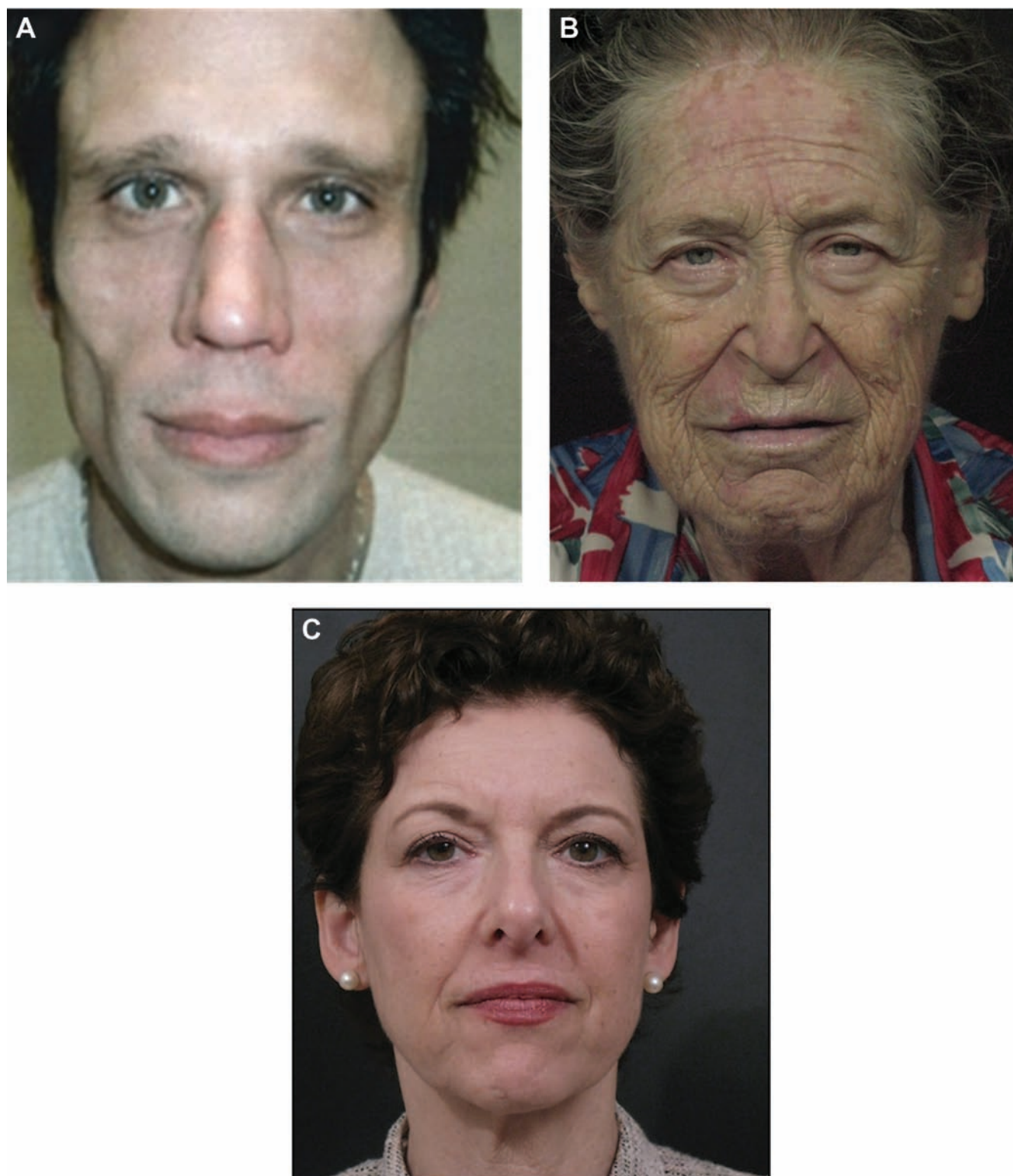


Figure 1. Parity vs. disparity of tissue loss. (A) This 45-year-old man needs added volume. (B) This 68-year-old woman primarily needs skin treatment. Patients in A and B both have a “one-tissue issue.” (C) This 61-year-old woman has parity of changes in the different structural tissue layers; volumization or a surgical lift would improve her appearance. Photos courtesy of Rebecca Fitzgerald, MD. Reprinted with permission from Jones DH. *Injectable Fillers: Principles and Practice*. Wiley-Blackwell, London 2010.

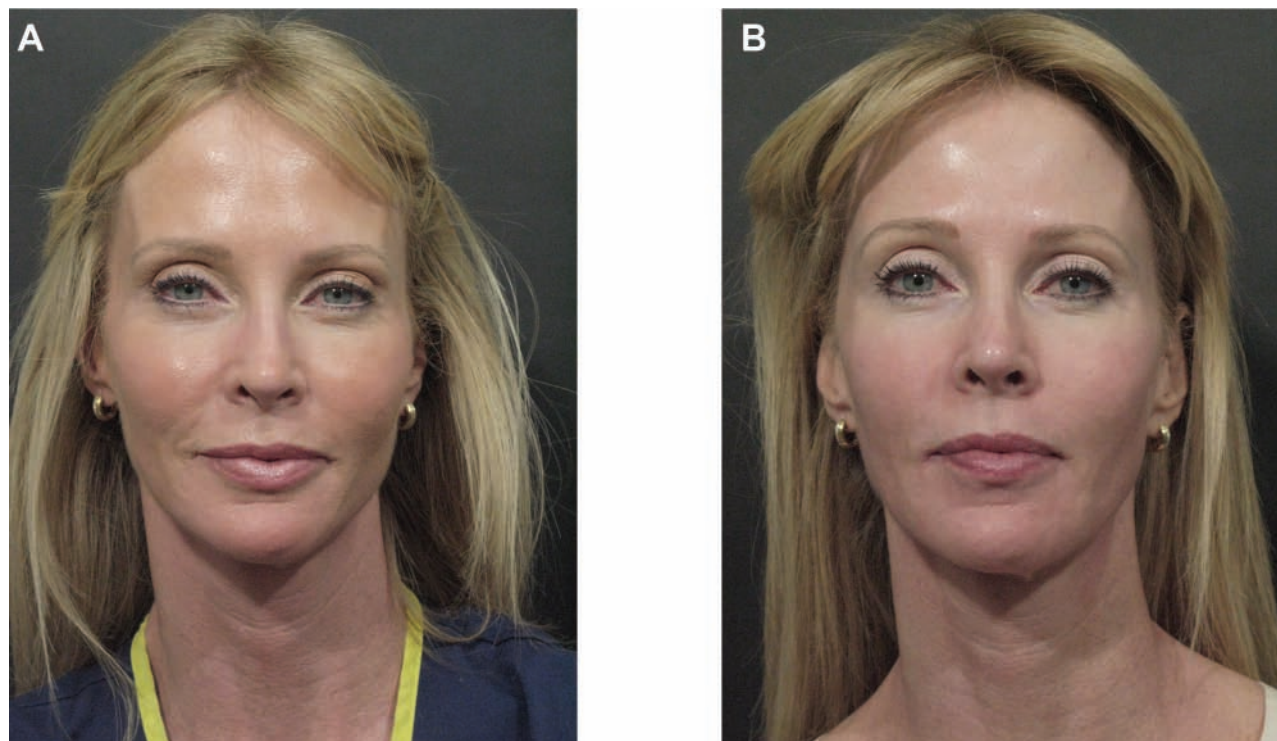

Figure 2. (A) This 39-year-old woman with an “overcorrected” appearance of the midface sought additional treatment. (B) After treatment with 10 mL of hyaluronic acid in the upper and lower thirds of the face, the patient’s face is blended back into perspective and has a more natural-appearing result. Photos courtesy of Rebecca Fitzgerald, MD. Reprinted with permission from Jones DH. *Injectable Fillers: Principles and Practice*. Wiley-Blackwell, London 2010.

lid laxity should improve when the brows and/or temples are filled. Patients with moderate or greater lid laxity are usually candidates for blepharoplasty.

Midface

For the midface, HA products and biostimulatory agents are indicated to address maxillary or mandibular bony remodeling, deep and superficial midface fat atrophy, or redistribution. However, practitioners should be aware that injection of bulking agents such as HA or CaHA in the canine fossa/pyriform aperture has been associated with vascular compromise and necrosis. A low-viscosity agent such as PLLA is a safer choice for supraperiosteal injections in the area. In male patients, overaugmentation of the midface should be avoided; too much midfacial fullness tends to be feminizing.

Correction of malar and submalar regions tends to improve nasolabial folds. If necessary, a small amount of HA or a biostimulatory agent can be injected to further soften or smooth nasolabial folds. The recommended approach to the application of injectable agents in this area is perpendicular to the labial fold, at the proximal portion of the nasolabial crease and medial to the infraorbital nerve.

Lower Face

When excess skin in the lower face is not an issue, injections of BTTA can be a nonsurgical alternative to a lower

facelift. The most commonly injected muscles in the lower face are those of the platysma and the depressor anguli oris. A softening effect occurs when the vertical neck bands are relaxed with injection of the platysmal muscles. Strategic weakening of the depressor anguli oris muscles allows the elevator muscles to raise the oral commissures.

In addition, BTTA injection to relax the mentalis muscle can correct a dimpled chin (also known as a “pebble” or “golf ball” chin). Relaxation of the orbicularis oris muscles (that is, the oral sphincter muscles) can ameliorate perioral rhytides, the radiating lines commonly referred to as “smoker’s lines.”

When injecting BTTA into the lower face, it is important to carefully choose dosages to avoid either completely relaxing or overweakening these muscles. For example, overweakening of the orbicularis oris muscles can lead to impairment of oral competence. Therefore, it is best to inject a low dose and have patients return for a follow-up visit two weeks later for evaluation; additional BTTA can be injected if further muscle relaxation is necessary.

BTTA injection of the levator levii superioris aequi nasi muscle—the muscle that is primarily responsible for the nasolabial fold—can improve the medial nasolabial fold. In addition, because this muscle also is responsible for about 2 to 3 mm of central upper lip elevation, this is a useful technique for patients whose smile reveals an excess upper gum (“gummy smile”). Very conservative amounts of 1 to 2 units should be injected in this area.

Although the lips are the predominant feature of the lower face, they should not be singularly approached as a

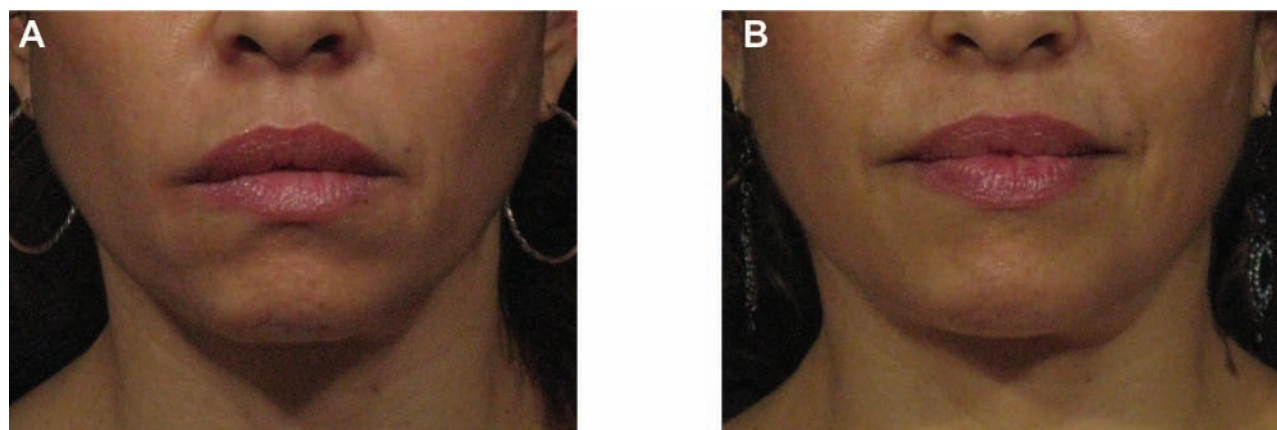


Figure 3. (A) This 46-year-old woman had adequate soft tissue in and around her lips but was lacking maxillary and mandibular bony support. (B) Treatment with poly-L-lactic acid (PLLA) in the canine fossa and along the medial mandible, as well as in the soft tissue of the cheeks, brought her lips more into balance even without direct treatment. Photos courtesy of Rebecca Fitzgerald, MD. Reprinted with permission from Jones DH. *Injectable Fillers: Principles and Practice*. Wiley-Blackwell, London 2010.

treatment target but should be considered within the context of perioral rejuvenation. HA is the agent of choice for this area (although it is an “off-label” use). It is important to recognize that natural-appearing projection cannot be achieved without also achieving support and fill of the surrounding tissue. This may include the fat deep to the orbicularis oris muscle in the upper and lower lip, as well as the fat deep to the mentalis muscle of the chin. Additionally, bony remodeling in a patient who has lost little if any soft tissue in the lips can leave the lips looking overly projected, even when no filler has been applied to the lip. In these patients, a nice result can be achieved with supraperiosteal treatments in the canine fossa and along the middle third of the mandible (Figure 3). Depressions along these bony areas can often be appreciated with deep palpation. With biostimulatory agents, the endpoint of any one treatment session is blanketing the surface area to be treated at that session. The total volumetric correction is addressed by the number of sessions, which should be communicated to the patient before treatment commences.

PRACTICE GUIDELINES

Several consensus articles on injectable shaping agents have been published in well-regarded sources that provide guidance in the specific applications of most of the available agents. Tables summarizing the highlights from those consensus guideline papers are reprinted here for readers’ convenience.

Matarasso and colleagues⁷ published guidelines for the use of the HA agents (Tables 1 and 2); guidelines from Carruthers and coworkers⁸ provide recommendations for the use of BTTA, HA, and a combination of the two (Tables 3-6). In the dermatology literature, Alam and colleagues⁹ published recommendations for the use of all of the injectable shaping agents.

Since the publication of these guidelines, PLLA has been approved by the US Food and Drug Administration (FDA) for cosmetic indications (in addition to its previous indication for correction of HIV-associated lipoatrophy). No consensus guidelines have been published previously regarding the cosmetic application of PLLA.

It should be noted that the cosmetic label approval was granted based on a study designed at the time of PLLA’s approval for the HIV lipoatrophy indication in 2004. This was a nasolabial fold study utilizing collagen as the comparator in order to adhere to a protocol already familiar to the FDA panel. The cosmetic indication reflects this study design. This means that some areas (such as the temples), treated safely for years “on label” in HIV lipoatrophy, are an “off-label” treatment for the cosmetic indication.

The appendix summarizes some simple yet critical technical considerations for the safe and effective use of PLLA. The authors, as a consensus panel of experienced users of this agent, offer these guidelines for consideration.

OVERCORRECTION SHOULD BE AVOIDED

A critical distinction exists between passive (or “replacement”) fillers and biostimulatory fillers. This difference in the mechanism of action has important clinical implications for safe and effective treatment with these devices.

Whereas passive fillers such as HA can be injected in any amount desired to achieve full correction at a single session, “too much, too soon” at a single session with collagen stimulators may lead to overcorrection. The desired host response in the specific application of tissue augmentation with these agents is a subclinical granulomatous inflammation leading to encapsulation and subsequent fibroplasia. These agents are biocompatible (by the Williams^{1,2} definition) when administered in a manner

Table 1. Facial Areas Most Commonly Treated With Nonanimal Stabilized Hyaluronic Acid

Facial Area	Consensus (% of Panel)			
	Most Common	Second Most Common	Third Most Common	Least Comfortable
Lips	17	54	29	6
Nasolabial folds	67	19	0	0
Glabellar complex	4	0	4	0
Cheeks	0	0	0	13
Tear troughs	8	0	17	56
Brow area	0	0	4	6
Chin/jawline	0	4	0	6
Depressed scar	0	0	0	13
Marionette lines	4	15	29	0
Oral commissures	0	8	17	0

Source: Matarasso et al.⁷ Reprinted with permission.

Table 2. Recommendations for Nasolabial Folds

Question	Response	Consensus (% of Panel)
What type of anesthetic would you use?	Topical	46
	Infiltrative	13
	Infraorbital block	42
	None	0
Which technique do you use for infrorbital blocks?	Cutaneous injection: 0.5-1 mL of anesthetic	0
	Intraoral injection: 1 mL of anesthetic	58
	Do not use infraorbital blocks	37
	Other	5
What injection technique would you utilize?	Serial puncture	38
	Linear threading	46
	Fanning	4
	Crosshatching	0
	Anterograde vs retrograde	8
	Other	4
Do you typically change the needle during treatment?	Frequently	18
	Infrequently	41
	Never	41
Typically, how much volume do you inject for two sides?	< 1.0 mL	5
	1.0 mL	35
	2.0 mL	60
	3.0 mL	0

Source: Matarasso et al.⁷ Reprinted with permission.

that allows for a predictable host response. Overcorrection at one session can lead to an overabundance of stimulating microparticles and a subsequent lack of predictability of the host response. For this reason, gradual, progressive correction and multiple treatment sessions are recommended for these agents.

CONCLUSIONS

The recommendations for facial rejuvenation with injectable shaping agents are the result of evidence in the literature as well as the accumulated clinical experience of the faculty.

Table 3. Consensus Recommendations on the Use of Botulinum Toxin Type A in the Upper Face

Region/Target Muscle(s)	Usual No. of Injection Points (Range): Unchanged From Original Recommendations	Total Starting Dose: Usual Range	
		Original Recommendations	Revised Recommendations
Glabellar complex (procerus, depressor supercilii, orbicularis oculi)	5 to 7; men may require more sites	Women: 20 to 30 U; men: 30 to 40 U	Women: 10 to 30 U; men: 20 to 40 U
Horizontal forehead lines (frontalis, but consider interactions with procerus, corrugators, and orbicularis oculi in overall facial shape)	4 to 8; more or fewer may be required based on anatomic and aesthetic evaluations	Women: 15 U, 10 to 20 U; men: 20 to 30 U	Women: 6 to 15 U; men: 6 to > 15 U
Crow's feet (lateral portions of the lateral orbicularis)	2 to 5 per side (higher in selected patients)	12 to 30 U	Women: 10 to 30 U; men: 20 to 30 U

Source: Carruthers et al.⁸ Reprinted with permission.

Table 4. Recommendations for the Use of Hyaluronic Acid Fillers in the Upper Face

Treated Area	Filler Volume	Comment
Glabella	< 0.25 mL in most patients; up to 0.5 mL	Stay superficial to mid-dermis and aspirate if necessary; avoid compressing vessels
Forehead	Depends on length of rhytide and degree of compensation; dictated by product to be used	Use softer products and avoid hard products that bead
Crow's feet	0.25 mL	Avoid stiff fillers and proceed gradually and with caution; place hyaluronic acid fillers deeper than soft collagen
Bunny lines	~ 0.10 mL	Use soft, malleable product

Source: Carruthers et al.⁸ Reprinted with permission.

Table 5. Recommendations for Treating the Midface With Botulinum Toxin Type A and Hyaluronic Acid Fillers

Treated Area	Filler Volume (% of faculty)	Comment
Malar smile lines	0.2 to 0.4 mL/side	Use deep dermal or subdermal injections and treat conservatively; may combine with resurfacing approaches or very small amounts of BoNTA; layering with different products can be used to address the etched-in superficial lines
Infraorbital hollow (arcus marginalis)	0.2 to 0.5 mL/side	Undercorrect in this area; do not inject deep to the orbital septum; this should be attempted only by experienced injectors
Nasojugal fold (tear trough)	0.1 to 0.2 mL/side (80%), 0.25 to 0.4 mL/side (20%)	Treat conservatively and reevaluate need for additional treatment in 2 to 4 weeks; this should be attempted only by experienced injectors
Nasolabial folds	0.5 to 1.0 mL/side (81%), 1.1 to 1.5 mL/side (19%)	Visualize the nasolabial folds as a triangular area to be filled rather than as a linear area; hyaluronic acid fillers can be layered with collagen or with each other; massage to distribute and contour fillers and reduce beading/clumping
Nasal dorsum and tip	< 0.5 mL	Can be used after rhinoplasty for refinement or to treat drooping that occurs with aging; BoNTA has been used to treat this area

Source: Carruthers et al.⁸ Reprinted with permission.

Table 6. Consensus Recommendations on the Use of Botulinum Toxin Type A in the Lower Face

Region/Target Muscle(s)	Usual No. of Injection Points (Range)	Total Starting Dose: Usual Range	
		Original Recommendations	Revised Recommendations (% of Faculty)
Perioral area, orbicularis oris	2 to 6; to start: 4 sites, 1 site per lip quadrant	4 to 10 U evenly divided among sites	4 to 5 U (75%) Note: treat lower lip in same session
Dimpled chin (peau d'orange), mentalis	1 to 2 (start with 1 midline or 2 symmetrical, lateral injections)	Women: 2 to 6 U; men: 2 to 8 U	4 to 5 U (56%); 6 to 10 U (44%)
Neck, platysmal bands, platysma	Women: 2 to 12 per band; men: 3 to 12 per band	Women: 10 to 30 U; men: 10 to 40 U	< 10 U/band (73%); 11 to 20 U/band (27%); 40 to 60 U total per neck per treatment

Source: Carruthers et al.⁸ Reprinted with permission.

With the recognition that treatment of any given area affects adjacent areas, a global approach to facial rejuvenation is recommended and a sequential, top-to-bottom approach is advised. The selection of agents for injection in specific areas should be based on a three-dimensional view, with careful consideration paid to the underlying craniofacial bone structure and the value of replacing lost bone volume with liquid implants—that is, biostimulatory fillers—at the supraperiosteal plane.

In academic trials, as well as in other published studies, the safety, efficacy, and durability of PLLA have been consistently demonstrated.¹⁰ Optimizing outcomes and minimizing adverse events with PLLA are not difficult but do require awareness of and attention to its specific and evolved injection methodology and are enhanced by a careful facial analysis before treatment. Performed correctly, PLLA injections are associated with low complication rates and high patient satisfaction.

Acknowledgments

The faculty acknowledge the writing assistance and editorial services including fact checking, referencing, and graphics provided by Global Academy for Medical Education, LLC, an Elsevier company, and Joanne Still, medical writer in the development of this continuing medical educational supplement. These services and assistance were funded by grant support from sanofi-aventis.

Disclosures

Dr. Fitzgerald is a consultant for sanofi-aventis. Dr. Graivier is a consultant for Coapt Medical, Elemé Medical, and Evera Medical and is on the speaker's bureau for Medicis and Sciton.

He has stock interests in BioForm Medical. Dr. Kane is a consultant and/or speaker for Allergan, Canfield, Coapt, Galderma, Johnson & Johnson, Medicis, Mentor, QMed, Revanace, sanofi-aventis, Shire, and Stiefel. He has stock interests in Allergan and Medicis. Dr. Lorenc is a consultant for Johnson & Johnson. Dr. Vleggaar is a consultant for sanofi-aventis. Dr. Werschler is a consultant for and has received grant support from Allergan, Clarisonic, Galderma, Genentech, MyoScience, sanofi-aventis, and SkinMedica. He is also a speaker for and has stock interests in Allergan, BioForm, Clarismiz, Medicis, MyoScience, sanofi-aventis, and SkinMedica. Dr. Kenkel is a consultant for Ethicon, Ethicon Endo-Surgery, and UltraShape. He has received grant support and/or equipment for research from Eclipse, Lumenis, Sciton, and UltraShape.

Funding

This CME activity is supported by an educational grant from sanofi-aventis. Funding was provided for the development and execution of an expert consensus roundtable and the editorial development, publication and accreditation of this continuing medical education supplement.

Statement of Peer Review

All supplement manuscripts submitted to *Aesthetic Surgery Journal* for publication are reviewed by the Guest Editor(s) of the supplement, by an outside peer reviewer who is independent of the supplement project, and by the Journal's Supplement Editor (who ensures that questions raised in peer review have been addressed appropriately and that the supplement has an educational focus that is of interest to our readership).

APPENDIX

Poly-L-lactic Acid Product Preparation and Injection Technique: Optimizing Outcomes

Unlike HA fillers, which may be applied in any amount desired to achieve full correction at a single session, the recommended strategy with collagen-stimulating fillers is to avoid the placement of an overabundance of stimulating microparticles that stimulate an undesired host reaction. Gradual, progressive correction may require multiple treatment sessions, as restoration of volume depends on each individual's response to building natural tissue. The following are some technical considerations for optimum use of PLLA.

PRODUCT RECONSTITUTION

- The PLLA product consists of microparticles, nonpyrogenic mannitol, and sodium carboxymethylcellulose and is supplied as a lyophilized powder. According to the package insert, PLLA should be reconstituted with 3 to 5 mL of sterile water for injection and then left to hydrate for at least two hours to disperse the particles. Lidocaine may be added to the suspension immediately before injection.
- Experience shows that a final dilution of at least 5 mL left to hydrate overnight is prudent. Adequate hydration time avoids the risk of injecting dry microclumps of material, which in turn will hydrate *in vivo*.

PRODUCT AMOUNT

- The amount of product used at any single treatment session should be determined solely and completely by the amount of surface area to be treated at that session using approximately 0.1 to 0.2 mL/cm².
- The final volumetric correction is addressed by the number of treatment sessions.
- The novice injector should be aware that it is initially difficult to resist the temptation to treat to full correction at any one session (although this may be possible with patients needing minimal treatment) and recall that the endpoint is "blanketing" the surface area to be treated at that session. The appropriate volume of product to be used at each session is therefore easily predetermined.

PRODUCT PLACEMENT

- For implantation of PLLA, a 1-mL or 3-mL syringe and a 25G (long or short) or 26G (short) needle should be employed.
- Depth of placement varies with location. The product is placed in the subcutaneous layer in the cheeks, preauricular area, nasolabial folds, and lower face with the crosshatch or fanning technique. Intradermal or superficial injections should be avoided, as persistent red granulomatous papules have been reported.
- Inject slowly in a crosshatch pattern when becoming familiar with the product. Fanning has the advantage of fewer needle sticks, although the novice injector should be vigilant to avoid multiple deposits at the apex of the fan.
- PLLA may be placed as depot injections supraperiosteally along the zygoma, maxilla, canine fossa/pyriform aperture, and mandible.
- Be aware that deep supraperiosteal treatments in the area of the canine fossa/pyriform aperture with bulking agents have led to ischemia and necrosis. It is unclear whether this vascular compromise is the result of occlusion of a vessel or vascular compression from adjacent swelling. Although the low viscosity of this product eliminates the risk of compression, a reflux maneuver should be performed routinely to avoid intravascular injection.
- Temple injections are placed deeply, under the temporalis fascia. The manufacturer's instructions are to place 0.05-mL depots in the temple; however, it is common practice among experienced injectors to place a 0.3- to 1.0-mL depot in this area, followed by application firm pressure and massage to distribute the product easily. If the product has been placed in the correct plane, there should be virtually no resistance to spreading. Again, a routine reflux maneuver before injection of product will eradicate any risk of inadvertent intravascular injection.
- Bear in mind that this product is mixed in water, creating a very low-viscosity solution compared to an HA gel. The novice injector must be vigilant to ration the product carefully to avoid inadvertent overcorrection.
- When implanting PLLA, deep supraperiosteal injections are done wherever possible, and subcutaneous injections are carried out where there is no underlying skeletal support, as outlined above in the section on technique.

PRODUCT PLACEMENT PRECAUTIONS

- Positional stability of a biostimulatory implant is critical to its safe injection.
- Avoid placement in or through areas of dynamic muscle movement. Frequent reports of "lip lumps" led to recommendations against the application of all collagen-stimulating devices in this area, including CaHA, PLLA, and PMMA. It is assumed that perioral muscle movement leads to a clumping of particles, which in turn leads to localized overcorrection and lumps.
- Injections in the modiolus or depressor anguli oris muscle may behave in a similar fashion. Additionally, periorbital supraperiosteal injections approached through the orbicularis oculi muscle have resulted in papules shown on histopathology to be clumps of product embedded in muscle. It may be that the path of the needle leaves a tract that allows more deeply placed material to be extruded during muscular contraction, resulting in clumping in the muscle.

TREAT, WAIT, ASSESS

- Remember that PLLA is not a filler but a stimulator of the host's collagen.
- Allow time for a response to develop before retreatment.
- Wait a minimum of four weeks between treatments to avoid "lumps and bumps."
- Be aware that although the majority of the response will be clinically apparent approximately four weeks after treatment, it may continue to improve for up to one year. This means that a patient who has had three monthly treatments may still see improvement at one year with no additional treatments (and an additional treatment in this case may result in an overvolumized face). This is especially important in young patients who need very little volume. If there is any question about the need for an additional treatment, it should not be done.

AFTERCARE

- Massage after every two to three injections and again at the end of the treatment.
- Have the patient massage over the next few days, according to the "rule of fives" (five minutes/five times daily/five days). Massage may increase circulation during the initial inflammatory response and has been shown to reduce the incidence of papules.

PREDICTING OUTCOMES

Volumization is difficult in patients with severe volume depletion, regardless of product choice. We have observed what seems to be a common perception, that patients with severe volume loss are the "optimal candidates" for a particular product. Keep in mind that with any product, revolumizing is expensive; recontouring and reshaping are not. Be aware that patient selection is at play here, not product choice. In a younger or fuller face, a very pleasing, cost-effective, and durable result can be achieved with a very conservative amount of product.

Source: Adapted from Fitzgerald RL. Advanced techniques for Sculptra. *J Drugs Dermatol* 2009;8(suppl):17-20.

REFERENCES

1. Williams DF. On the mechanisms of biocompatibility. *Biomaterials* 2008;29:2941-2953.
2. Williams D. Revisiting the definition of biocompatibility. *Med Device Technol* 2003;14:10-13.
3. Fitzgerald R, Graivier MH, Kane M, et al. Update on facial aging. *Aesthetic Surg J* 2010;30(suppl):11S-24S.
4. Matros E, Garcia JA, Yaremchuk MJ. Changes in eyebrow position and shape with aging. *Plast Reconstr Surg* 2009;124:1296-1301.
5. Lambros V. Volumizing the brow with hyaluronic acid fillers. *Aesthetic Surg J* 2009;29:177-179.
6. Lambros V. Observations on periorbital and midface aging. *Plast Reconstr Surg* 2007;120:1367-1376.
7. Matarasso SL, Carruthers JD, Jewell ML. Consensus recommendations for soft-tissue augmentation with nonanimal stabilized hyaluronic acid (Restylane). *Plast Reconstr Surg* 2006;117(suppl):3S-34S.
8. Carruthers JD, Glogau RG, Blitzler A. Facial Aesthetics Consensus Group Faculty. Advances in facial rejuvenation: Botulinum toxin type a, hyaluronic acid dermal fillers, and combination therapies—consensus recommendations. *Plast Reconstr Surg* 2008;121(suppl):5S-30S.
9. Alam M, Gladstone H, Kramer EM, et al. ASDS guidelines of care: injectable fillers. *Dermatol Surg* 2008;34(suppl 1):S115-S148.
10. Butterwick K, Lowe NJ. Injectable poly-L-lactic acid for cosmetic enhancement: learning from the European experience. *J Am Acad Dermatol* 2009;61:281-293.